

LEUKEMOID REACTION RESULTING FROM GRANULOCYTE COLONY-STIMULATING FACTOR PRODUCING UROTHELIAL CARCINOMA OF THE RENAL PELVIS

Han-Ching Lin,¹ Chee-Yin Chai,^{2,3} Yue-Chiu Su,² Wen-Jeng Wu,^{1,4} and Chun-Hsiung Huang^{1,4}
Departments of ¹Urology and ²Pathology, Kaohsiung Medical University Hospital, and
Departments of ³Pathology and ⁴Urology, Faculty of Medicine, College of Medicine,
Kaohsiung Medical University, Kaohsiung, Taiwan.

Leukemoid reaction is defined as a reactive leukocytosis in response to infection, inflammation, or therapeutic agents such as growth factors and malignancy. We report a case of leukemoid reaction resulting from granulocyte colony-stimulating factor producing urothelial carcinoma of the renal pelvis as evidenced on immunohistochemical analysis.

Key Words: granulocyte colony-stimulating factor, leukemoid reaction, renal pelvis, urothelial carcinoma
(*Kaohsiung J Med Sci* 2007;23:89–92)

Carcinomas producing granulocyte colony-stimulating factor (G-CSF) are known to be extremely malignant and to carry a poor prognosis [1]. Primary neoplasms manifesting granulocytosis were first reported in 1951 [2]. Bradley and Metcalf [3] have demonstrated the biologic effects of G-CSF on granulocytic and mononuclear cell proliferation.

Renal pelvic carcinoma producing G-CSF is rare, which is reported in the English literature. We provide a case of leukemoid reaction from G-CSF producing urothelial carcinoma (UC) of the renal pelvis.

CASE PRESENTATION

A 75-year-old man presented with left flank pain and gross hematuria for 3 months. He was admitted to our

hospital and underwent serial examinations. Physical examination showed a left flank mass with tenderness. The leukocyte count was 39,800/ μ L with 88% segmented form. There was no evidence of infectious disease. No abnormal finding in urinary bladder was noted on cystoscopic examination. The report of urine cytology was negative. Abdominal computed tomography (Figure 1A) showed a mass measuring 12 \times 13 cm in the upper pole of the left kidney with lung metastasis. Then, angiography (Figure 1B) showed a hypervascular mass, which was supplied by the anterior division of the left renal artery. Under impression of renal cell carcinoma due to the hypervascular pattern seen with angiography, the tumor was selectively embolized by gelfoam pledgets and metallic coil preoperatively (Figure 1C). The patient underwent radical nephrectomy and para-aortic lymphadenectomy. The course of treatment was smooth and he was discharged on the 10th postoperative day.

To our surprise, the diagnosis on the pathologic report was not renal cell carcinoma as we had suspected preoperatively. It was reported as infiltrating UC of the renal pelvis (staging: pT4N0M1) with direct

Received: August 1, 2006

Accepted: August 18, 2006

Address correspondence and reprint requests to: Dr Wen-Jeng Wu, Department of Urology, Kaohsiung Medical University Hospital, 100 Tzyou 1st Road, Kaohsiung 807, Taiwan.

E-mail: urology@kmu.edu.tw

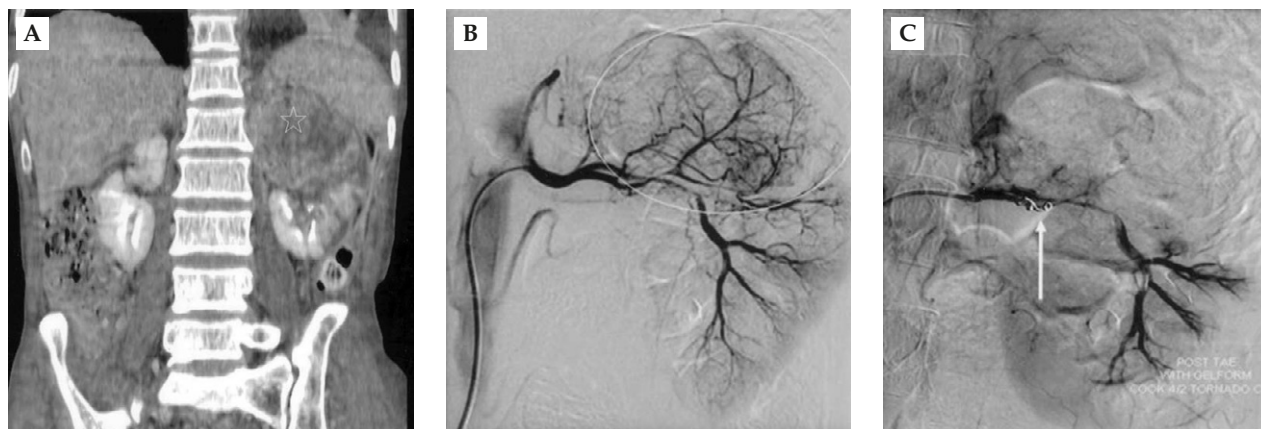

Figure 1. (A) Computed tomography: coronal reconstructive section shows a 12 × 13 cm mass in the upper pole of the left kidney (star). (B) Angiography shows a hypervascular mass located in the left upper kidney (circle). (C) Selective embolization of the tumor by the metallic coil is successful (arrow).

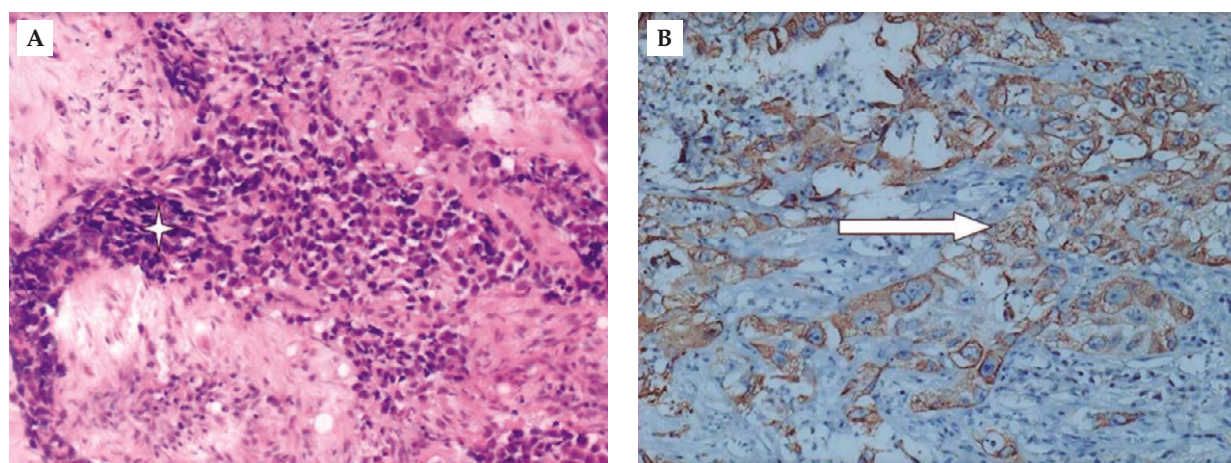


Figure 2. (A) Infiltrating hyperchromatic cancer cells (star) with high N/C ratio in desmoplastic fibrous stroma (hematoxylin & eosin, 100×). (B) Immunohistochemical stain shows that the tumor cells are immunoreactive for G-CSF (arrow).

adrenal gland invasion. Furthermore, the tumor cells were immunoreactive for G-CSF, vascular endothelial growth factor (VEGF), and hypoxia-inducible factor 1 (HIF-1) (Figure 2).

The white blood cell (WBC) count normalized within 2 weeks postoperatively. Subsequently, systemic chemotherapy with MVAC was started. Unfortunately, the WBC count gradually increased without any infectious focus, and he died 10 weeks postoperatively.

DISCUSSION

Malignant neoplasms are often accompanied by leukocytosis in the absence of any acute infectious disease or blood disorder [4]. The G-CSF secreted by

tumor cells has been considered to be a cause of leukocytosis. Several studies have demonstrated G-CSF producing tumors, which are characterized by leukemoid reaction and mainly involve mature neutrophils.

Elevated serum G-CSF level was shown to be associated with poor prognosis in patients with urinary bladder tumor [5].

It was reported that G-CSF produced by transitional cell carcinoma (TCC) of the bladder augments its autocrine growth [6]. Hematopoietic differentiation of TCC, resulting in acquisition of G-CSF production and G-CSF receptor expression, is another possibility supported by the same study [6].

Renal pelvic carcinoma producing G-CSF is rare. Higaki et al reported the first case in 2001 [7], followed

by Terao et al [8] in 2005. Although neither of them received surgical resection, both of them died within 8 weeks of diagnosis.

In this case, the initial diagnosis was renal cell carcinoma due to its hypervascularity in the angiography films and negative findings on urine cytology and cystoscopy. Therefore, embolization was done routinely before radical nephrectomy to avoid excess blood loss intraoperatively.

Although the operation went quite smooth and leukemoid reaction subsided 2 weeks after operation, he died 10 weeks postoperatively.

Like the previous two cases [7,8], the tumor cells were immunoreactive for G-CSF. The result of immunohistochemistry study of the tumor cells can make sense of the interrelationships between leukemoid reaction and the G-CSF producing tumor cells in our case. Radical nephrectomy offers a cytoreduction effect and normalization of the leukocyte count can be obtained postoperatively even if the tumor has metastasized to the lung.

Overexpression of proangiogenic factors by tumor cells is one mechanism by which tumors can promote neovascularity. VEGF has also been shown to be proangiogenic and to promote invasion and metastasis of human TCC [9]. Transcription of the VEGF gene is known to be driven by HIF-1, and recent evidence has suggested that cellular HIF-1 levels are raised not only by hypoxia but are also increased in the presence of reactive oxygen species [10].

Hypervascularity is an uncommon character of UC of renal pelvis. Interestingly, it was well demonstrated in the case we presented here. We found that it may be explained by the ability of the tumor cells to produce VEGF and HIF-1.

VEGF is a survival factor that protects both tumor and endothelial cells from exposure to environmental stresses such as hypoxia or acidosis [11]. Recent reports indicate that VEGF also protects tumor cells against chemotherapy-induced apoptosis [12]. It was proved previously by the relative overexpression of VEGF observed within residual tumors after MVAC chemotherapy [9]. It may reflect the clonal selection resulting from the death of tumor cells expressing low levels of VEGF and the survival of tumor cells expressing relatively high levels of VEGF, which rendered them relatively resistant to chemotherapy-induced apoptosis [9]. Regarding our case, this may explain the poor response to chemotherapy since the tumor was

immunoreactive for VEGF. Although the results of his treatment course were disappointing, radical surgery seems to be the most effective treatment. Enhancement of tumor growth by many cytokines was proved by our immunohistochemical study. Target therapy to the specific cytokine is likely to be an alternative treatment in the future.

REFERENCES

1. Asano S, Urabe A, Okabe T, et al. Demonstration of granulopoietic factor(s) in the plasma of nude mice transplanted with a human lung cancer and in the tumor tissue. *Blood* 1997;49:845-52.
2. Fahey RJ. Unusual leukocyte responses in primary carcinoma of the lung. *Cancer* 1951;4:930-4.
3. Bradley TR, Metcalf D. The growth of mouse bone marrow cells *in vivo*. *Aust J Exp Med* 1986;44:287-99.
4. Hughes WF, Highley CS. Marked leukocytosis resulting from carcinogenesis. *Ann Intern Med* 1952;37:1085-8.
5. Mizutani Y, Okada Y, Terachi T, et al. Serum granulocyte colony-stimulating factor levels in patients with urinary bladder tumor and various urological malignancies. *Br J Urol* 1995;76:580-6.
6. Tachibana M, Miyakawa A, Tazaki H, et al. Autocrine growth of transitional cell carcinoma of the bladder induced by granulocyte-colony stimulating factor. *Cancer Res* 1995;55:3438-43.
7. Higaki I, Hirohashi K, Fukushima S, et al. Renal pelvic carcinoma producing granulocyte colony-stimulating factor: report of a case. *Surg Today* 2001;31:266-8.
8. Terao S, Yamada Y, Shirakawa T, et al. Granulocyte-colony stimulating factor producing urothelial carcinoma of renal pelvis. *Int J Urol* 2005;12:500-2.
9. Inoue K, Slaton JW, Karashima T, et al. The prognostic value of angiogenesis factor expression for predicting recurrence and metastasis of bladder cancer after neoadjuvant chemotherapy and radical cystectomy. *Clin Cancer Res* 2000;6:4866-73.
10. Page EL, Robitaille GA, Pouyssegur J, et al. Induction of hypoxia-inducible factor-1 alpha by transcriptional and translational mechanisms. *J Biol Chem* 2002;277:48403-9.
11. Biroccio A, Candiloro A, Mottolese M, et al. Bcl-2 overexpression and hypoxia synergistically act to modulate vascular endothelial growth factor expression and *in vivo* angiogenesis in a breast carcinoma line. *FASEB J* 2000;14:652-60.
12. Katoh O, Takahashi T, Oguri T, et al. Vascular endothelial growth factor inhibits apoptotic death in hematopoietic cells after exposure to chemotherapeutic drugs by inducing MCL1 acting as an antiapoptotic factor. *Cancer Res* 1998;58:5565-9.

腎盂泌尿上皮癌分泌白血球生長激素 導致類白血病反應

林漢青¹ 蔡志仁^{2,3} 蘇月秋² 吳文正^{1,4} 黃俊雄^{1,4}

高雄醫學大學附設醫院 ¹泌尿科 ²病理科

高雄醫學大學 醫學系 ³病理科 ⁴泌尿科

類白血病反應常常出現於身體對感染，發炎，和藥物 (如生長激素) 所產生血液中白血球上升的情形。只有少數惡性腫瘤有類似的情形。我們提供一個罕見的病例是有關腎盂泌尿上皮癌分泌白血球生長激素導致類白血病反應。並且也用免疫特殊染色來證實。

關鍵詞：白血球生長激素，類白血病反應，腎盂，泌尿上皮癌

(高雄醫誌 2007;23:89-92)

收文日期：95 年 8 月 1 日

接受刊載：95 年 8 月 18 日

通訊作者：吳文正醫師

高雄醫學大學泌尿科

高雄市807三民區自由一路100號