

# CELLULAR NEUROFIBROMA WITH ATYPIA MIMICS SARCOMA: REPORT OF A CASE WITH IMMUNOHISTOCHEMICAL STAINING PATTERN ANALYSIS AND LITERATURE REVIEW

Shih-Wen Hu,<sup>1,3</sup> Shih-Lin Hwang,<sup>4</sup> Wei-Chen Lin,<sup>5</sup> and Kun-Bow Tsai<sup>1,2,3</sup>

Departments of <sup>1</sup>Pathology, <sup>4</sup>Neurosurgery and <sup>5</sup>Medical Imaging, Kaohsiung Medical University Hospital, <sup>2</sup>Kaohsiung Municipal Hsiao-Kang Hospital, and <sup>3</sup>Department of Pathology, Faculty of Medicine, College of Medicine, Kaohsiung Medical University, Kaohsiung, Taiwan.

A case of two sporadic cellular neurofibromas with atypia and one widespread hyalinization neurofibroma of the lumbar spine in a 51-year-old man without evidence of neurofibromatosis-1 is reported. Cellular neurofibroma with atypia is an unusual variant. The definite criteria for low-grade and high-grade malignant peripheral nerve sheath tumors as well as cellular neurofibroma are not well defined in the literature. The clinical significance of atypical cellular neurofibroma has rarely been systematically studied. To our knowledge, the concomitance of cellular architecture and cytologic atypia is rarely documented, and this is a rare report of atypical cellular neurofibroma. The recognition of this entity is of great importance to both pathologists and clinicians because atypical cellular neurofibroma is clever at masquerading both histologically and cytologically as a sarcoma; therefore, a precise diagnosis of this variant is essential because of the differences in treatment and clinical behavior between benignancy and malignancy. We also examined the immunohistochemical characteristics of CD34 positive cells and focal high expression of p53 up to 73% encountered in our case. To our knowledge, seldom have series or case reports elucidated this phenomenon.

**Key Words:** CD34, malignant peripheral nerve sheath tumor, neurofibroma, neurofibromatosis-1, p53, sarcoma  
(*Kaohsiung J Med Sci* 2006;22:508–14)

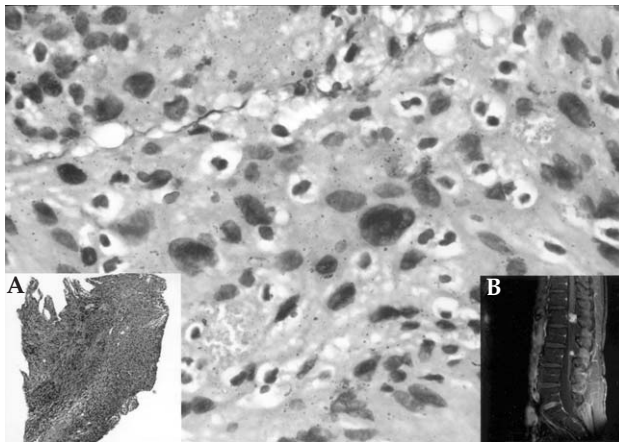
We found only one individual diagnosed with atypical cellular neurofibroma from the pathology files of the Department of Pathology, Kaohsiung Medical University Hospital, the medical center of south Taiwan, between 1988 and 2005. We went through the literature on the subject and found that this was an unusual

entity. We reviewed all the section slides and had the full immunohistochemical panel needed for differential diagnosis of the disease. The section slides were reviewed by two pathologists. The clinical information was obtained from the medical records and the surgeon. Here, we report an additional case of atypical cellular neurofibroma originating from the first and third lumbar spines (L1 and L3) in the same patient. We discuss the reason for discordance between the frozen and permanent section slides. The magnetic resonance imaging (MRI), CD34 positive cells, and areas of high p53 staining, which were up to 73% in our case, are described. The literature on this subject is reviewed.

Received: December 12, 2005      Accepted: March 24, 2006  
Address correspondence and reprint requests to: Dr Kun-Bow Tsai, Department of Pathology, Kaohsiung Municipal Hsiao-Kang Hospital, 482 Shan-Ming Road, Kaohsiung 812, Taiwan.  
E-mail: kbtsai@cc.kmu.edu.tw

## CASE PRESENTATION

A 51-year-old Taiwanese man had complained of numbness in bilateral thighs and legs for several months. He was admitted to our neurosurgical ward on September 3, 2003. No pelvic pain, constipation, urinary urgency, weight loss, hematuria, or dysuria was reported. Apart from having a medical history of hypertension for years, and a past history of soft tissue mass around the first sacral foramen that was excised in 1998, there was no other significant past medical history. His physical examination and laboratory data were unremarkable. MRI showed two relatively well-defined lesions involving L1 and L3. They were both lobulated intradural extramedullary nodules roughly 18 mm and 10 mm in greatest diameter. MRI with contrast enhancement showed nodules with homogeneous enhancement. A few tiny low signal dots within the homogeneously enhanced lesion were noted that manifested no contrast enhancement; the largest was approximately 2.5 mm (Figure 1). The cornus medullaris was compressed. In addition, the previous surgical site of L5–S1 disc displayed a low T2 signal and enhancement. There were spurs at lumbar spines, though their alignment was unremarkable. The abnormal signal in the thecal sac was not identified, though there was no abnormal signal

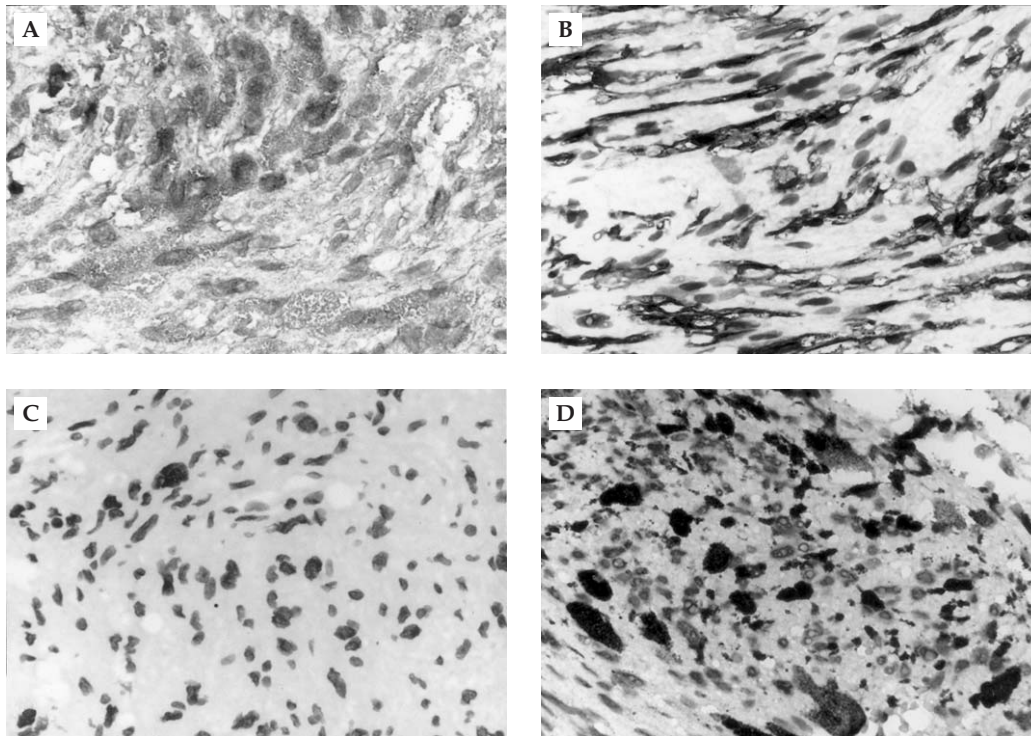


**Figure 1.** Tumor with nuclear atypia. Note the presence of enlarged cells with bizarre nuclei, smudged chromatin, and abundance of cytoplasm (hematoxylin and eosin [H&E], original magnification 400 $\times$ ). Inset A: highly cellular spindle cells of the atypical cellular neurofibroma in fascicular pattern of growth (H&E, original magnification 40 $\times$ ). Inset B: sagittal T1-weighted image with contrast enhancement shows two well-defined tumors. However, one tiny but obvious low-signal intensity area is seen within the L1 tumor.

intensity over the bony vertebra. The paraspinous soft tissue remained unremarkable. Radiographic findings of both lesions were interpreted as arteriovenous malformation. The differential diagnosis included meningioma, ependymoma, and metastatic disease. Surgery was subsequently performed. At surgery, L1 had a round intradural and extramedullary nodule, and L3 had a diffuse infiltrating lesion within the terminal filament. The tumor was entirely removed. The patient was regularly followed up in our clinics and had an unremarkable postoperative course. So far, there has been no evidence of recurrence.

The excised surgical specimen for frozen section consisted of 10 tiny grayish-white tissue fragments, measuring up to 1.2 $\times$ 0.6 $\times$ 0.5 cm in size. The excised surgical specimen submitted later comprised seven solid grayish-white tissue fragments in two separate bags measuring up to 1 $\times$ 1 $\times$ 0.4 cm in size. The cut surface was white-tan. No hemorrhage, necrosis, or cystic changes were identified grossly. The frozen section slides confirmed that the histology of the neoplasm was a solid hypercellular tumor. It was formed either by short interlacing fascicles or by whorled patterns of spindle cells. It was characterized by foci of a palisading-like pattern, hemorrhage, and inflammation. The compact and highly cellular spindle cells showed somewhat hyperchromatic nuclei with eosinophilic cytoplasm and indistinct cell borders. There was moderate nuclear atypia with occasional cells having large bizarre nuclei. No active mitoses and necrosis were identified (Figure 1). The tentative frozen section diagnosis was meningioma. The differential diagnosis was schwannoma.

The permanent section slides showed a similar histology as the frozen section slides. Nevertheless, some cells had larger and more smudged nuclei without distinct nucleoli (Figure 1). In some areas, the spindle cells had long wavy nuclei with tapered ends. Some had oval, round, short spindle nuclei, or had nuclear pseudo-inclusions. Foci of small, thin, and slit-like vessels and vacuolated cells were seen. Immunohistochemical features of the spindle cells were strongly positive for S-100 (Figure 2A) and vimentin. In focal areas, an extreme minority of cells had strong positive staining for glial fibrillary acidic protein (GFAP), synaptophysin, and neurofilament protein (NFP). Some collagen fibers were seen in Masson's trichrome stain. Cytokeratin, CD117 (c-Kit), epithelial membrane antigen, and smooth muscle actin were all



**Figure 2.** Immunohistochemical features. (A) S-100 diffusely positive. (B) Focal strong CD34 immunopositivity. (C) Ki-67 diffusely negative. (D) Focal extremely high p53 expression. (All immunohistochemical stain and original magnification 400 $\times$ .)

negative. CD34 was diffusely negative except for the areas of vacuolated cells (Figure 2B). Proliferation index (Ki-67) and positive p53 staining were scored by counting the percentage of positive cells in one high power field (HPF) in the section slide. Then, the positive rate was the average of the positive percentage of all HPFs in the whole section slide. Ki-67 was 0% (Figure 2C). The positive rate of p53 staining varied, ranging from less than 1% to as high as 73% (Figure 2D); however, the average percentage of p53 in the whole section slide was approximately 2%.

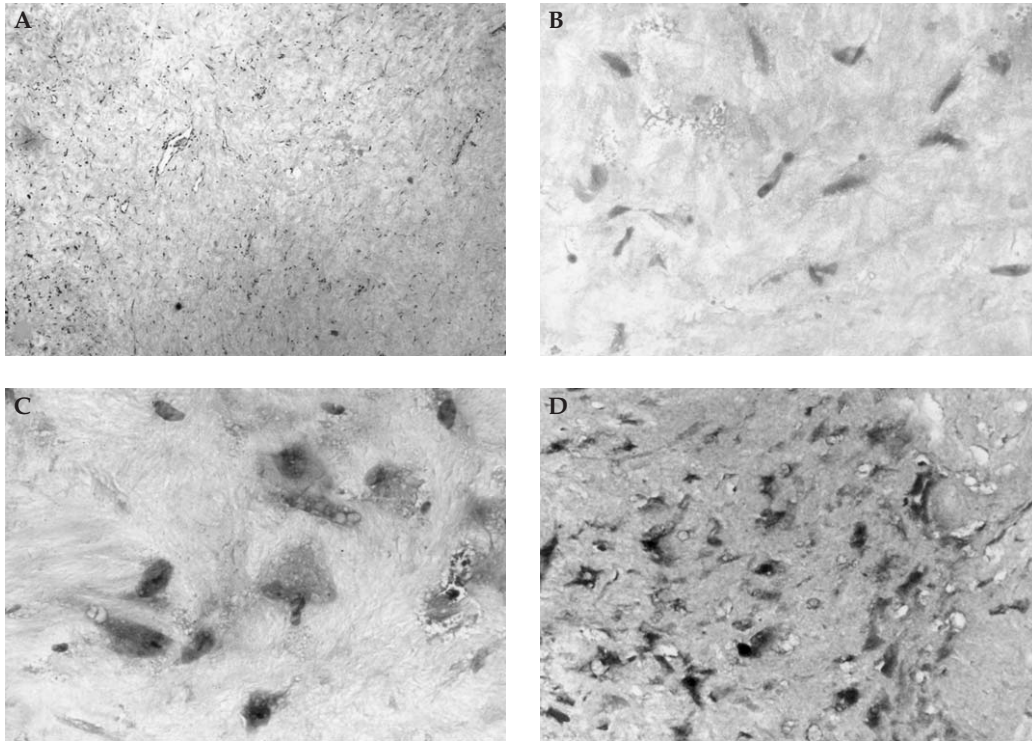
The section slides from the previous surgery in 1998 were reviewed. They showed extensive hyalinization with a low density of spindle cells and bland nuclei (Figure 3A). Some cells had wavy nuclei. There was no hemorrhage, necrosis, or active mitoses (Figure 3B). Immunohistochemical study showed collagen component seen on Masson's trichrome stain (Figure 3C). S-100 was diffusely positive (Figure 3D).

## DISCUSSION

Neurofibroma can occur either as sporadic solitary nodules or as multiple lesions in individuals with

neurofibromatosis-1 (NF1) [1]. It is composed of neoplastic Schwann cells, fibroblasts, perineurium-like cells, and cells intermediate between fibroblasts and perineurial-like cells embedded in a collagen matrix [2,3]. The diagnosis of conventional neurofibroma is easy due to the above characteristic pathologic features. Atypical neurofibroma is neurofibroma with cytologic atypia, and cellular neurofibroma described by others is one with increased cellularity [3]. In our case, the whole tumor was exclusively hypercellular with a high ratio of cytologic atypia. The histologic pattern was quite different from conventional neurofibroma and those described in the literature [3]. These histologic features occasionally make it difficult to distinguish atypical cellular neurofibroma from low-grade malignant peripheral nerve sheath tumor (MPNST), cellular schwannoma, and other spindle cell tumors [4]. Cellular schwannoma has the characteristics of high cellularity and lack of Antoni B pattern with occasional ancient changes that comprise nuclear pleomorphism, hyperchromasia, and microcystic or macrocystic change [5,6]. In our patient, the histopathologic features were suggestive of cellular schwannoma. Both neurofibroma and cellular schwannoma are positive for S-100 [2,7]. While the





**Figure 3.** (A, B) Photomicrographs of specimen show elongated or wavy nuclei with extensive hyalinization (hematoxylin and eosin, original magnification 40 $\times$  in A and 400 $\times$  in B). (C) Immunohistochemical staining shows abundant collagen in the background (original magnification 400 $\times$ ). (D) Immunohistochemical staining shows diffusely positive staining of S-100 protein in the tumor cells (original magnification 400 $\times$ ).

histopathologic features of cellular schwannomas have been described, atypical cellular neurofibromas have rarely been studied. To our knowledge, there is no report that details how atypical cellular neurofibromas may be differentiated from cellular schwannoma. We even encountered a conceptual challenge in one paper that some nerve sheath tumors may contain histologic components of both neurofibromas and schwannomas, suggesting a closer relationship between the two than previously recognized [8]. In our case, a tiny focal area of entrapped neurons and a few cells that were strongly positive for GFAP, NFP, and synaptophysin were seen. The collagen in the matrix is not easily appreciated histopathologically, but could be clearly outlined on Masson's trichrome stain. Only one veterinary paper appears to have such a full panel of immunohistochemistry with detailed immunohistochemical-staining pattern fully studied like ours [9]. Based on the histopathologic features and those described in the literature, the histologic constituents of our case were not composed of pure Schwann cells—small wonder then that we had the immunohistochemical pattern of GFAP, NFP, synaptophysin,

and Masson's trichrome stains. Furthermore, no hyaline thick-walled vessel was seen on our section slides. Hence, the presence of the above findings rules out cellular schwannoma. More difficult is the differential diagnosis between atypical cellular neurofibroma and low-grade MPNST [1,4]. Malignant transformation from neurofibroma to MPNST has been fully studied, especially in patients suffering from NF1 (von Recklinghausen's disease) [3,4,10,11]. Although expanding studies on MPNST have emerged, there is no universal consensus on how MPNST should be diagnosed due to its morphologic diversity [2,4,11]. This is true especially for low-grade MPNST [2]. The lack of standardized diagnostic criteria makes the diagnosis of low-grade MPNST more difficult [2]. Some studies have found the presence of any mitoses significant, while others place the emphasis on hypercellularity, diffuse nuclear enlargement at least three times the size of conventional neurofibroma nuclei, and diffuse hyperchromasia [2]. Therefore, several ancillary studies comparing the expression of immunohistochemical variables between benign peripheral nerve sheath tumors and MPNST have been published [12,13]. Among these

immunohistochemical variables, p53 and Ki-67 were the most widely studied and potential markers in detecting neurofibroma with malignant transformation [12–15], which captured our interest. While the significance has been confirmed in a majority of studies, there are variable methods of estimating the p53 and Ki-67 markers [12–16]. The range between benign and malignant components of MPNST also varied greatly [12–16]. Studies have shown that p53 plays an important role in malignant transformation [14,16]. In our case, p53 was strongly positive mostly in the atypical cells as previously reported [14]. Also, the range of p53 staining varied greatly from less than 1% to 73%. If the biopsy specimen is small and accidental in this high p53 staining area, malignancy may be misdiagnosed. When we counted all the p53 positive cells in every HPF on our slides, we found that the average p53 positivity was about 2%. In our case, Ki-67 was 0%. We believe that no report has previously described this odd staining pattern. Consequently, we found that the sample size of the surgical specimen, the method of counting the positive cells, and an appropriate immunohistochemistry panel are all important in the differential diagnosis. It is dangerous to make a diagnosis of malignancy solely on one immunohistochemical marker. At least two markers are needed.

Focal vacuolated cells and CD34 intense immunoreactivity in our case drew our attention because these cells in neurofibroma are seldom referred to in textbooks. We found a few reports elucidating the characteristics of these cells [17–19]. A few unusual histologic features encountered in neurofibroma include rosette formation, focal rhabdomyomatous feature, vacuolated cells, and myxoid change. We found that the previous surgical specimens in this patient had the unusual feature of extensive hyalinization. The vacuolated cells in the surgical specimens this time had another one of the several unusual histologic features of neurofibroma and were confirmed to be a highly characteristic feature of endoneurial neurofibroma [17]. To our knowledge, no such feature in atypical cellular neurofibroma has been reported by other authors in the literature. This study is the first to introduce this component of atypical cellular neurofibroma.

We found well-circumscribed and homogeneous lesions with strong enhancement on MRI. Tiny low-signal cystic-like areas were also seen. Our radiologist thought that cystic change or vessels might be possible as an atypical feature of neurofibroma. The image was

in accordance with a previous report [20]. We assume that MRI is not a reliable tool for distinguishing benign and malignant peripheral nerve sheath tumors.

Based on the histopathologic features of heterogeneous groups of cells, clinical presentation, and the appropriate immunohistochemistry panel, we made the diagnosis of atypical neurofibroma [4,6,7,9,11]. In conclusion, a thorough study of the histopathologic features, along with clinical presentation, and the utilization of ancillary studies, particularly an appropriate panel of immunohistochemistry, is helpful in the diagnosis of atypical cellular neurofibroma [11].

## REFERENCES

1. Sungur N, Uysal A, Koçer U, et al. Early malignant change in a solitary neurofibroma not associated with neurofibromatosis: a case report. *Eur J Plast Surg* 2005; 28:105–8.
2. Woodruff JM. Pathology of tumors of the peripheral nerve sheath in type 1 neurofibromatosis. *Am J Med Genet* 1999;89:23–30.
3. Lin BT, Weiss LM, Medeiros LJ. Neurofibroma and cellular neurofibroma with atypia: a report of 14 tumors. *Am J Surg Pathol* 1997;21:1443–9.
4. Yamaguchi U, Hasegawa T, Hirose T, et al. Low-grade malignant peripheral nerve sheath tumor: varied cytological and histological patterns. *J Clin Pathol* 2003;56: 826–30.
5. Henke AC, Salomao DR, Hughes JH. Cellular schwannoma mimics a sarcoma: an example of a potential pitfall in aspiration cytodiagnosis. *Diagn Cytopathol* 1999; 20:312–6.
6. Laforga JB. Cellular schwannoma: report of a case diagnosed intraoperatively with the aid of cytologic imprints. *Diagn Cytopathol* 2003;29:95–100.
7. Koizumi Y, Utsunomiya T, Yamamoto H. Cellular schwannoma in the oral mucosa. *Acta Otolaryngol* 2002;122:458–62.
8. Feany MB, Anthony DC, Fletcher CD. Nerve sheath tumours with hybrid features of neurofibroma and schwannoma: a conceptual challenge. *Histopathology* 1998;32:405–10.
9. Chijiwa K, Uchida K, Tateyama S. Immunohistochemical evaluation of canine peripheral nerve sheath tumors and other soft tissue sarcomas. *Vet Pathol* 2004; 41:307–18.
10. Molenaar WM, Dijkhuizen T, van Echten J, et al. Cytogenetic support for early malignant change in a diffuse neurofibroma not associated with neurofibromatosis. *Cancer Genet Cytogenet* 1997;97:70–2.
11. Molina CP, Putegnat BB, Logroño R. Fine-needle aspiration cytology and core biopsy of malignant peripheral

- nerve sheath tumor of the uterus: a case report. *Diagn Cytopathol* 2001;24:347–51.
12. Kindblom LG, Ahlden M, Meis-Kindblom JM, et al. Immunohistochemical and molecular analysis of p53, MDM2, proliferating cell nuclear antigen and Ki67 in benign and malignant peripheral nerve sheath tumours. *Virchows Arch* 1995;427:19–26.
  13. Wilkinson JS, Reid H, Armstrong GR. Malignant transformation of a recurrent vestibular schwannoma. *J Clin Pathol* 2004;57:109–10.
  14. Mikami Y, Hidaka T, Akisada T, et al. Malignant peripheral nerve sheath tumor arising in benign ancient schwannoma: a case report with an immunohistochemical study. *Pathol Int* 2000;50:156–61.
  15. Liapis H, Marley EF, Lin Y, et al. p53 and Ki-67 proliferating cell nuclear antigen in benign and malignant peripheral nerve sheath tumors in children. *Pediatr Dev Pathol* 1999;2:377–84.
  16. Watanabe T, Oda Y, Tamiya S, et al. Malignant peripheral nerve sheath tumour arising within neurofibroma. An immunohistochemical analysis in the comparison between benign and malignant components. *J Clin Pathol* 2001;54:631–6.
  17. Hattori H. Vacuolated cells in neurofibroma. An immunohistochemical study. *J Cutan Pathol* 2005;32:158–61.
  18. Khalifa MA, Montgomery EA, Ismiil N, et al. What are the CD34+ cells in benign peripheral nerve sheath tumors? Double immunostaining study of CD34 and S-100 protein. *Am J Clin Pathol* 2000;114:123–6.
  19. Hirose T, Tani T, Shimada T, et al. Immunohistochemical demonstration of EMA/Gli1-positive perineural cells and CD34-positive fibroblastic cells in peripheral nerve sheath tumors. *Mod Pathol* 2003;16:293–8.
  20. Mautner VF, Friedrich RE, von Deimling A, et al. Malignant peripheral nerve sheath tumours in neurofibromatosis type 1: MRI supports the diagnosis of malignant plexiform neurofibroma. *Neuroradiology* 2003;45:618–25.

# 與肉瘤極相似的異生細胞纖維神經瘤： 免疫組織化學染色類型分析的病 例報告和文獻回顧

胡士文<sup>1,3</sup> 黃旭霖<sup>4</sup> 林威辰<sup>5</sup> 蔡坤寶<sup>1,2,3</sup>

高雄醫學大學附設醫院 <sup>1</sup>病理科 <sup>4</sup>神經外科 <sup>5</sup>醫學診斷部

<sup>2</sup>高雄市立小港醫院 病理科

<sup>3</sup>高雄醫學大學 醫學院醫學系病理學科

在這裡舉一個偶爾發生的異生細胞纖維神經瘤，病患是 51 歲男性，沒有纖維神經瘤病的病史，異生細胞纖維神經瘤發生在腰椎的兩個不同地方和另一處的透明化纖維神經瘤。異生細胞纖維神經瘤是纖維神經瘤一個不尋常的變異型，不過在文獻上，對於惡性周圍神經鞘腫瘤的高低惡性度和細胞纖維神經瘤的病理標準診斷準則，一直都沒有明確的定義，文獻上已經有細胞纖維神經瘤的系統性研究，不過據我們所知，纖維神經瘤同時具有結構上高細胞密度和細胞學上是異生的案例非常少，而在此我們報告一個纖維神經瘤同時具有結構上高細胞密度和細胞學上是異生的案例。對於病理醫師和臨床醫師來說，區分出這個纖維神經瘤的變異型非常重要，因為異生細胞纖維神經瘤在組織學上和細胞學上都非常類似肉瘤，因此正確的診斷出這個纖維神經瘤的變異型是必要的，因為臨床上對於良性和惡性腫瘤的治療和腫瘤行為表現是不同的。在此我們討論 CD34 陽性的細胞特性和局部 p53 高達 73% 表現的有趣現象，據我們所知，少有論文或案例報告專門討論此現象。

**關鍵詞：** CD34，惡性周圍神經鞘腫瘤，纖維神經瘤，纖維神經瘤病-1，p53，肉瘤  
(高雄醫誌 2006;22:508-14)

收文日期：94 年 12 月 12 日

接受刊載：95 年 3 月 24 日

通訊作者：蔡坤寶醫師

高雄市立小港醫院病理科

高雄市812小港區山明路482號