



available at www.sciencedirect.com



journal homepage: <http://www.kjms-online.com>



ORIGINAL ARTICLE

Anatomic and functional outcome after surgical removal of idiopathic macular epiretinal membrane

Po-Yen Lee ^a, Kai-Chun Cheng ^{b,c,*}, Wen-Chuan Wu ^{a,d}

^a Department of Ophthalmology, Kaohsiung Medical University Hospital, Kaohsiung, Taiwan

^b Department of Ophthalmology, Kaohsiung Municipal Hsiao-Kang Hospital, Kaohsiung, Taiwan

^c Graduate Institute of Medicine, Kaohsiung Medical University, Kaohsiung, Taiwan

^d Department of Ophthalmology, Faculty of Medicine, College of Medicine, Kaohsiung Medical University, Kaohsiung, Taiwan

Received 8 October 2010; accepted 3 December 2010

Available online 21 April 2011

KEYWORDS

Cataract surgery;
Combined;
Idiopathic;
Macular epiretinal
membrane;
Membrane peeling
surgery

Abstract The purpose of this study is to investigate the functional and structural outcomes of surgical treatment of eyes with idiopathic macular epiretinal membrane (ERM). Clinical records of 21 patients (22 eyes) who underwent macular ERM removal with at least 6 months of postoperative follow-up period were reviewed retrospectively. All patients were treated with pars plana vitrectomy and ERM peeling surgery. Fourteen patients also underwent cataract surgery at the same time. Pre- and postoperative visual acuity (VA), intraocular pressure (IOP), and macular thickness along with postoperative adverse events were all recorded. The mean follow-up was 8.5 ± 3.2 months. Three eyes were pseudophakic and 19 eyes were phakic preoperatively. Five phakic eyes undergoing simple ERM peeling surgery had worsened cataracts, and vision was recovered after subsequent cataract extraction surgery. Mean preoperative IOP was 13.1 ± 4.2 mmHg, which did not differ significantly postoperatively ($p = 0.228$). One patient had increased IOP postoperatively and needed topical antiglaucoma treatment. Thirteen eyes showed visual improvement, and six eyes became worse during the follow-up. Mean preoperative best-corrected VA was 0.36 decimal equivalent, which was then converted to logarithm of the minimum angle of resolution (logMAR 0.502 ± 0.259) for statistical analysis; this had improved to a mean of 0.536 decimal equivalent (logMAR 0.38 ± 0.35) at the final follow-up. Mean central macular thickness (CMT) also significantly declined ($p < 0.0001$). From an analysis of dividing patients into two subgroups according to clinical severity [macular pucker (MP) and cellophane maculopathy (CM)], measured mean CMT of both groups demonstrated significant reduction at final follow-up (MP, $p < 0.0001$; CM, $p = 0.005$). Mean final best-corrected VA also reached significant improvement in MP group ($p = 0.008$). However, in the CM group, no significant change in VA was observed ($p = 0.52$). Besides, VA

* Corresponding author. Department of Ophthalmology, Kaohsiung Medical University Hospital, No. 100, Zihyou 1st Road, Sanmin Dist, Kaohsiung 807, Taiwan.

E-mail address: maco69@gmail.com (K.-C. Cheng).

measurements in the MP group had improved significantly to that of CM ($p = 0.037$). The measured CMTs of the MP group had also reduced significantly ($p = 0.046$) compared with those of the CM group. In conclusion, membrane peeling surgery can lead to a significant reduction of macular edema in patients with idiopathic macular ERM. The advantages of combined peeling and cataract surgery will achieve maximum positive visual outcome. Copyright © 2011, Elsevier Taiwan LLC. All rights reserved.

Introduction

As is known, idiopathic macular epiretinal membrane (ERM) is defined as fine, semitranslucent, nonvascular, fibrocellular membrane on the inner retinal surface along the internal limiting membrane (ILM) [1]. Affected patients may present with variable degrees of visual impairment, including metamorphopsia, micropsia, and visual loss. ERM formation characterizes a number of pathological changes occurring in vitreoretinal junctions. The origin is attributed to accessory retinal glial cells, fibrous astrocytes, and Müller cells migrating from neurosensory retina migrating through surface and breaks of ILM. These membranes could also be composed of macrophages and retinal pigment epithelial (RPE) cells [2]. Posterior vitreous detachment or separation is present in almost all eyes with idiopathic membranes [3,4]. The clinical characteristics vary according to the degree of the membrane. Gass [5] has proposed a classification scheme for ERMs. Translucent membranes unassociated with retinal distortion are Grade 0 [cellophane maculopathy (CM)]. Membranes that cause irregular wrinkling of the inner retina are Grade 1 [crinkled CM]. Opaque membranes that cause obstruction of the underlying vessels and full-thickness retinal distortion are Grade 2 [macular pucker (MP)]. Besides, histological evidence shows that most surgical excised samples have demonstrated the presence of ILM along with ERM [6,7].

Pars plana vitrectomy with membrane peeling is the standard treatment for surgical removal of the ERM, with reported rates of visual improvement ranging between 67% and 82%. However, 12.5–63% of patient will develop progressive nuclear sclerotic cataracts following membrane peeling surgery [8]. In addition, many eyes have concurrent idiopathic ERM and cataracts, making surgery more difficult. Therefore, combined cataract extraction and vitrectomy has been described for idiopathic ERM.

In the present study, we have evaluated the anatomic and functional outcome after vitrectomy combined with cataract surgery. Besides, we also evaluated the surgical outcome of different type of macular ERM.

Methods

Patient selection

This study is a retrospective, nonrandomized study and includes 21 consecutive patients who were diagnosed with idiopathic ERM between January 2008 and April 2009. All patients gave written consent to the described surgical procedure. The following tests were performed before surgery: Visual acuity (VA) measurement and Amsler grid. If

the result of VA was worse than 20 of 50 or intolerable visual distortion was present even with better VA (>20 of 50), patients were advised to accept the operation at the Department of Ophthalmology of Kaohsiung Medical University during this period. Eyes with a minimum of 6 months of follow-up were included in this study.

Exclusion criteria were the presence of a macular hole, prior retinal tears, previous vitreoretinal surgery, and any other retinal pathology that could potentially alter anatomic or functional results. Besides, neither of the patients had a history of ocular hypertension and glaucoma nor was a steroid responder.

Surgical technique

Vitrectomy and cataract surgery was performed in all cases by the same surgeon using the Accurus vitreoretinal surgical system (XS4 with 3D technology; Alcon Pharmaceuticals Ltd, Taipei, Taiwan). Phacoemulsification of cataract through a clear corneal incisional wound was performed at first, then the anterior chamber was tamponaded by Healon GV (Abbott Medical Optics Inc., CA, USA), one of the ophthalmic viscosurgical devices and the incisional wound was closed temporarily. The conjunctiva was displaced and oblique angled incisions were made in the sclera through the pars plana with a 19-gauge needle. A core vitrectomy was performed with standard 20-gauge system and the posterior hyaloid membrane was separated from the retina when necessary. Half a milliliter of suspension of triamcinolone acetonide (TA) (Kenalog) with concentration of 40 mg/mL was injected through one trocar orifice for staining of ERM and it aids in visualization of ERM. It was washed out after vitreous tamponade for at least 5 minutes. Visualization of the fundus was achieved using a planoconcave contact lens for macular peeling. The macular ERM was peeled in the macular area using end-gripping forceps. After that, a posterior chamber intraocular lens (AcryS of single-piece—Natural IOL; Alcon) implantation followed closing the wound of the sclerotomy by sutures of Vicryl 7-0. The conjunctiva was repaired with Vicryl 7-0 sutures at the end of the surgery.

If patients were either under clear-nucleus status or pseudophakia or refused to receive cataract extraction surgery at the same time although already having senile cataract, only simple vitrectomy with membrane peeling surgery was performed. These two groups of patients were then divided and compared with the outcome parameters.

Statistical analysis

Before treatment and at each follow-up visit, the ophthalmic examination included best-corrected visual acuity (BCVA)

Table 1 Patients' demographics and outcomes during follow-up

Characteristics	Value	<i>p</i>
Patients, <i>n</i>	21	
Total eyes	22	
Male:female, <i>n</i> (%)	10 (47.3):11 (52.4)	
Mean age, yr	60 (SD: 10.1, range: 26–75)	
Lens: status (baseline) (eyes)		
Phakic:pseudophakic, <i>n</i> (%)	19 (86.7):3 (14.3)	
Lens status (last follow-up)		
Pseudophakic, <i>n</i> (%)	22 (100)	
Mean follow-up, mo	8.5 (SD: 3.2, range: 6–17)	
Mean IOP (mmHg)		
Baseline	13.1 (SD: 4.2, range: 7–26)	0.228
Last follow-up	12.6 (SD: 4.3, range: 7–20)	
IOP	1 case (IOP: 31, 1 wk postoperatively)	
Mean BCVA (logMAR)		
Baseline	0.502 (SD: 0.259, range: 0.2–1)	0.11
Last follow-up	0.38 (SD: 0.35, range: 0–1)	
Snellen chart		
BCVA gain more than two lines, <i>n</i>	10	
Mean lines gain	1.95 (SD: 2.95, range: –4, 6)	
Mean CMT (μ m)		
Baseline	454 (SD: 105.5, range: 310–692)	<0.0001
Last follow-up	315.8 (SD: 42.9, range: 244–411)	
Mean reduction	138.91 (SD: 82.30, range: 45–318)	

BCVA = best-corrected visual acuity; CMT = central macular thickness; IOP = increased IOP; IOP = intraocular pressure; logMAR = logarithm of the minimum angle of resolution; SD = standard deviation.

using Snellen charts to determine equivalent decimal acuity, which was then converted to a logarithm of the minimum angle of resolution (logMAR) for statistical analysis. VA and macular thickness were summarized using mean \pm standard deviation (SD). Intraocular pressure (IOP) was calculated by using pneumotometry. Slit-lamp biomicroscopy and fundus examination with dilated pupils were performed. Retinal architecture and central macular thickness (CMT) measurement were evaluated using the optical coherence tomography (OCT) Stratus (Carl Zeiss Meditec Inc., Dublin, CA, USA).

The main outcome parameters were changes in BCVA, CMT, and IOP between baseline and the postoperative follow-up examinations at 1 day, 1 week, 1 month, 2 months, 4 months, and the last follow-up at a minimum of 6 months. Cataract progression was also evaluated for those not receiving concurrent cataract surgeries. All data were statistically analyzed using the two-tailed *t* test using SPSS statistical software (Version 14.0; SPSS Inc., Chicago, IL, USA). Paired *t* tests were run to compare differences between baseline and final data. We also divided patients into subgroups for further analysis according to received surgical types and the clinical characteristics according to Gass classification. That means all the cases were compared between the combined cataract surgery and simple peeling surgery groups, and MP (Grade 2 by Gass classification) and CM (Grade 0 and Grade 1) groups using independent samples *t* test. A *p* value of 0.05 was considered statistically significant.

Results

Twenty-two eyes of 21 patients were included in this study. Data are summarized in Table 1. There were 10 (47.4%) male and 11 (52.6%) female patients. Mean patient age at the time of surgery was 60 years (SD: 10.1, range: 26–75 years). The mean follow-up was 8.5 months (SD: 3.2, range: 6–17 months). Nineteen (87%) eyes were phakic and three (13%) were pseudophakic at the time of surgery. Fourteen of the 19 phakic eyes received combined surgery. The other five phakic eyes received simple peeling surgery.

Mean preoperative IOP was 13.1 ± 4.2 mmHg (range: 7–26 mmHg). One patient (Patient 10) presented an elevated IOP (>21 mmHg) 10 days postoperatively and needed topical antihypertensive treatment. At the final follow-up visit, mean IOP was reduced to 12.6 ± 4.3 mmHg (range: 7–20 mmHg) that did not differ significantly from the IOP preoperatively (*p* = 0.228; two-tailed *t* test).

Examples of preoperative and postoperative OCT thickness maps (Patient 10) are shown in Fig. 1; the postoperative maps of this patient showed a completely peeled area and decrease in retinal thickness with recovered VA.

Results of VA and retinal thickness measurements are shown in Fig. 2. Mean preoperative BCVA was 0.36 decimal equivalent (logMAR 0.50 ± 0.26 , range: 1.0–0.2), which improved significantly to a mean of 0.54 decimal equivalent

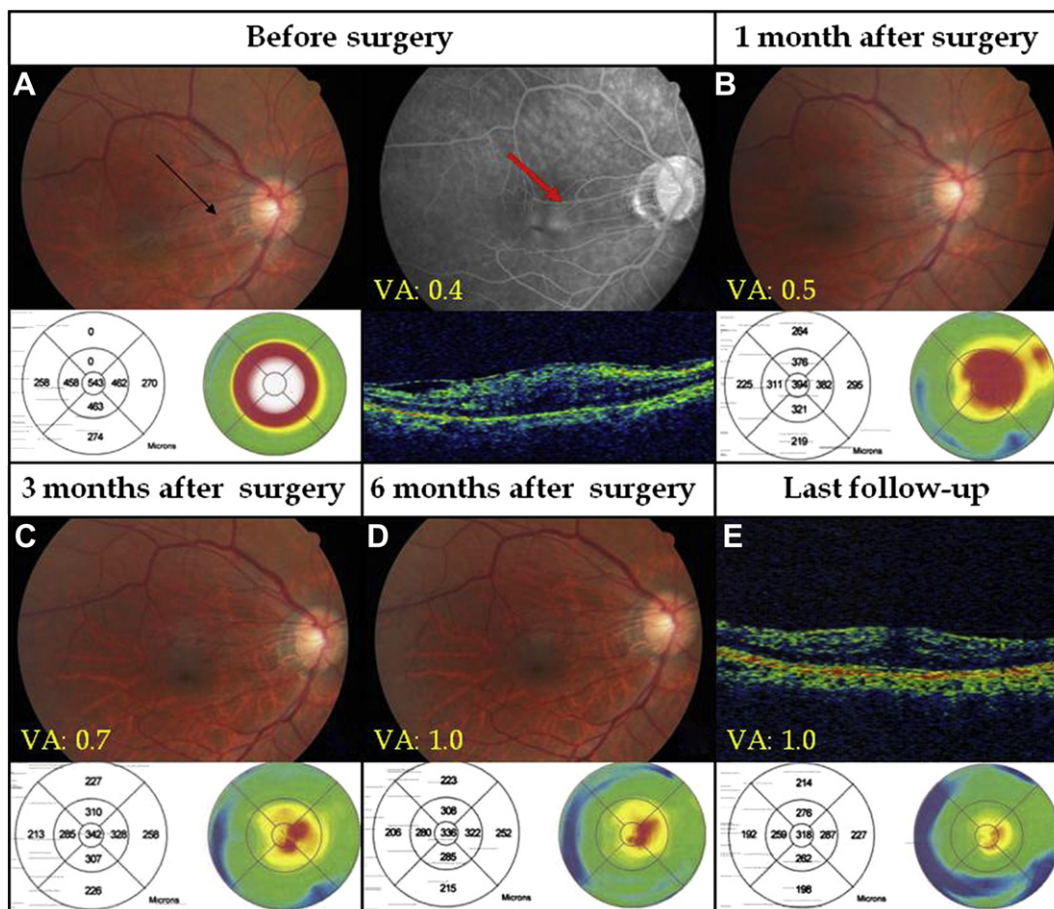


Figure 1. Selected case (Patient 10) of color fundus photography and fluorescein angiography taken preoperatively (A) showing vascular tethering (arrow) and fluorescein leakage (red arrow). Note the very fast reduction of CMT between the baseline measurement (543 μm) and the OCT examination at 1 month postoperatively (394 μm); (B) parallel increase in BCVA, suggesting a beneficial effect in the postoperative phase. (A) Preoperative BCVA was 0.4 (Snellen chart); (B) OCT 1 month after surgery showing a clear decrease in the CMT to 394 μm . BCVA has increased to 0.5; (C) Three months after surgery, CMT of 342 μm , BCVA has increased to 0.7; (D) Six months later, CMT of 336 μm , BCVA was 1.0; (E) OCT at the last follow-up 15 months later showing a CMT of 318 μm . BCVA has remained at 1.0. BCVA = best-corrected visual acuity; CMT = central macular thickness; OCT = optical coherence tomography; VA = visual acuity.

(logMAR 0.38 ± 0.35 , range: 1–0) at the final follow-up ($p = 0.11$, two-tailed t test). The BCVA improved by 1.95 ± 2.95 Snellen lines (range: –4, 6). Ten (45%) patients demonstrated a gain of more than two lines. Mean CMT measured with OCT was $454 \pm 105.5 \mu\text{m}$ (range: 331–680 μm) at baseline, which was significantly reduced at the final follow-up to $315.8 \pm 42.9 \mu\text{m}$ (range: 244–441 μm) ($p < 0.0001$; two-tailed t test). However, although there was a significant decrease in CMT, the values at final follow-up were still significantly greater than those for the fellow eyes ($242.73 \pm 107.74 \mu\text{m}$; $p = 0.009$) (Fig. 2). None of the eyes developed recurrent macular ERM at the final visit.

Of the 19 phakic eyes operated on for only idiopathic ERM or combined with cataract extraction procedure, there was no significant difference in VA between the two groups preoperatively ($p = 0.59$, independent samples t test). However, all of the five phakic eyes operated on with simple peeling surgery had clinical worsening of cataracts, and the measured BCVA were decreased significantly at the fourth time of our follow-up (mean 1.83 months after

peeling surgery) compared with those of the combined surgery group ($p = 0.023$) (Fig. 3). Therefore, all the five patients were convinced that they should receive cataract extraction with phacoemulsification and intraocular lens implantation subsequently. As a result, four of these patients (80%) had significantly improved VA after cataract extraction surgery ($p = 0.031$). At the final follow-up, the difference of the mean BCVA was not statistically significant between the combined surgery group and the traditional simple peeling surgery group ($p = 0.74$).

We divided our series into two subgroups of MP and CM. Preoperative and postoperative data are summarized in Table 2, and they show no significant difference between these two subgroups. Following up the measurement clinical data postoperatively, mean CMT measured with OCT both demonstrated significant reduction at final follow-up (MP group, $p < 0.0001$; CM group, $p < 0.005$). Mean BCVA also reached significant improvement at final follow-up in the MP group ($p = 0.008$). However, no significant change in VA was observed in the CM group ($p = 0.52$).

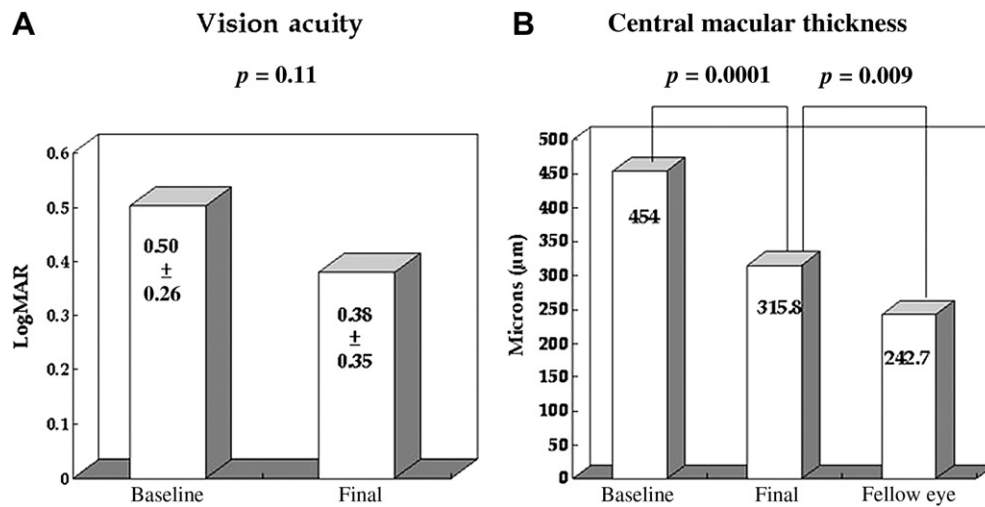


Figure 2. (A) Visual acuity (logMAR) before (baseline) and after surgery (final); (B) Central macular thickness before and after surgery by OCT scan; final values were compared with the healthy fellow eyes. logMAR = logarithm of the minimum angle of resolution; OCT = optical coherence tomography.

Comparisons of the amount of improvement of the same parameters at the end of the follow-up period between these subgroups are also shown in Table 2; functional (BCVA) and structural (CMT) outcome measurements all showed more improvement in the MP group than in the CM group (increased BCVA: $p = 0.037$; decreased CMT: $p = 0.046$).

Discussion

Several authors have described combined cataract extraction and vitrectomy to treat various vitreoretinal disorders [9–13]. In the present series, combined surgeries resulted in an improvement in VA similar to that reported in the literature. It is a safe and effective technique for the treatment of idiopathic macular ERM. The most frequently reported complication of ERM removal is cataract progression, which frequently requires surgical treatment within

the 2 years after the vitrectomy performed for idiopathic ERM surgery [14]. If the surgeons wait longer for cataract surgery, they could be faced with denser cataracts and preoperative complications. Besides, ERM disease is related to aging; some eyes have concurrent idiopathic ERM and cataracts, making vitrectomy surgery more difficult related to blurred media. Therefore, ERM is probably one of the most popular indications for combined surgery [8,14,15]. In our study, progressed nuclear sclerotic cataract developed in the five phakic eyes within the 2 months after the vitrectomy was performed without concurrent cataract extraction surgery. Besides, significant progressed BCVA were noted after cataract formation when compared with the combined surgery group. After receiving cataract extraction surgery, all of the five cases had significant visual improvement, and the functional results were equivalent in both groups until the final follow-up. This means that, related to simple vitrectomy and peeling surgery, combined surgery allowed shortening of postoperative recovery time to achieve maximum final VA, a better view of the retina during and after surgery, and reduction of cost [8,16]. In the present study reported by Dugas et al. [15], the outcomes of combined and consecutive surgeries (membrane and cataract surgery performed separately) were assessed, and they found no statistical differences between the VA improvement in both groups, but VA recovery was quicker in the combined surgery group (6 months after surgery). However, unlike our series, these authors chose to perform ERM and ILM removal first and then cataract surgery. Their aim was to avoid any visual distortion resulting from the IOL or corneal edema. On the other hand, we preferred performing cataract extraction first before vitrectomy, to avoid more difficulties during cataract surgery in a vitrectomized eye and to give clearer surgical visualization. Posterior chamber intraocular lens were implanted at last to avoid any interference while performing peeling surgery.

Whether peeling of ILM or not remains controversial. The effects of removal of ILM have been reported in the

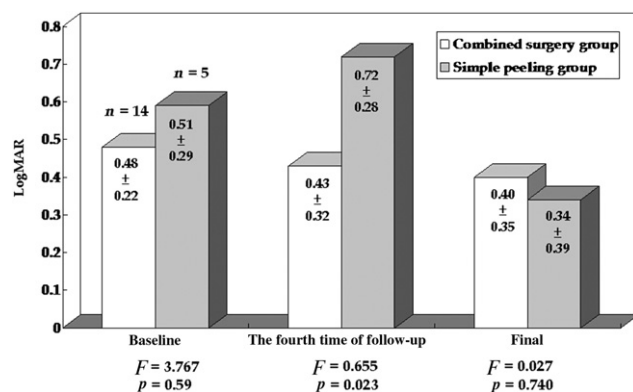


Figure 3. Comparison between the combine surgery group and the simple peeling surgery group for best-corrected visual acuity (logMAR) pre- and postoperatively. logMAR = logarithm of the minimum angle of resolution.

Table 2 Clinical data of the two subgroups pre- (baseline) and postoperatively (final follow-up)

Type	n	Age	Gender (male: female)	Preoperative data		Postoperative data		Comparison of pre- and postoperative data		VA improvement ≥2 Snellen lines, n (%)	VA improvement (baseline BCVA ± final BCVA)	CMT change (%)
				BCVA (log MAR)	CMT (µm)	Final BCVA (logMAR)	Final CMT (µm)	BCVA (p)	CMT (p)			
Macular pucker	14 (15 eyes)	64.14 ± 6.96	9:6	0.51 ± 0.29	482.87 ± 115.68	0.28 ± 0.28	322.73 ± 45.58	0.008	<0.0001	8 (53.3)	0.23 ± 0.29	30.21 ± 10.48
Cellophane maculopathy	7 (7 eyes)	58.33 ± 10.98	3:4	0.48 ± 0.19	394.43 ± 38.38	0.59 ± 0.40	309.43 ± 35.42	0.520	0.005	2 (28.6)	-0.1 ± 0.39	24.85 ± 11.85
p		0.217	0.452	0.93	0.065	0.13	0.505				0.037	0.046

The p value is calculated using independent samples t test (age, preoperative mean BCVA, preoperative mean central macular thickness) and Chi-square tests (gender). BCVA = best-corrected visual acuity; CMT = central macular thickness; logMAR = logarithm of minimal angle of resolution.

literature. In a pilot study by Park et al. [17], peeling of ILM along with ERM produced better outcomes in VA and less recurrence rates than ERM peeling alone. Similarly, Bovey et al. [18] found that ILM removal was associated with better final VA and a lower incidence of reoccurrence of epimacular membrane. However, Sivalingam et al. [19] reported that eyes treated with ILM removal together with ERM removal had a less favorable visual outcome than eyes that had only ERM removal. We think the result could be explained by the improved knowledge of the pathological process of ERM formation, indicating that most surgical samples derived from this surgery have shown the presence of the ILM along with ERM. Snead et al. [20,21] reported increased cellularity associated with hyperconvolution of the ILM and novel basement membrane formation on the removed ERM specimens. Gibran et al. [22] had reported that the ILM in the ERM represents a secondary basement membrane and that the surgical plane of dissection for most ERM peels is between the ERM and the native ILM in several different ways. Terasaki et al. [23] found that focal electroretinography (ERG) amplitudes were decreased after vitrectomy with ILM peeling rather than vitrectomy without ILM peeling. They attributed these results to "some dysfunction or physiological changes in the Müller cells." In the study by Tari et al. [24], the use of multifocal ERG, OCT, and standard achromatic perimetry showed changes in macular function and structure postoperatively. Besides, they found samples of peeled ILM, including Müller cell footplate processes according to electron microscopy findings.

The Müller cell plays a key role in the maintenance of retinal homeostasis and functionality, and hence dysfunction results in modulating the synaptic transmission in the retinal neural circuitry. Therefore, we did not prefer the procedure of double peeling. We believe that the ILM plays an important role in retinal function because it is the basal lamina of Müller cells that are involved in the generation of ERG b-waves. The preservation of the acellular structure would help to keep the intact function of the retina.

In our study, most patients had improved functional and structural outcome after undergoing complete surgery. Although there was a decrease in macular thickness postoperatively, the values were still greater than those for the fellow eyes ($p = 0.009$). That means that although the membrane-traction force was released after ERM peeling surgery, the presence of residual retinal abnormalities still persist and are unrecoverable. This may be because of a gliotic damage of the RPE and photoreceptors resulting from the long-standing traction toward the retina by the ERM, and the residual macular edema remains.

Besides, there were four of seven patients with decreased VA in the group of CM postoperatively, but only 1 of 15 patients with decreased VA in the MP group. Besides, the trend toward decreased macular edema and increased VA reached statistical significance in the MP group compared with the CM group (Table 2). That means the clinical characteristics of MP may have better surgical prognosis than CM. Many previous studies have attempted to determine the distinction between CM and MP. Snead et al. [20] reported that by using light microscopy and immunocytochemistry for examination, the hyperconvolution and duplication of ILM in surgically removed

ERM of CM and MP were striking in distinctive features and suggested the primary etiology for CM and MP may originate within ILM.

In summary, the relatively poorer functional and anatomical outcome in the CM group may be explained by the extent of adhesion and relationship between the ERM and the vitreous chamber, even in the inner retina. CM is the early stage of the ERM formation in which glial cells migrate through breaks in the inner lamina and proliferate along the surface of ILM, forming a translucent membrane tightly adhered to the ILM layer. Complete surgical removal of cellophane-like ERM without double peeling of inner ILM layer is very difficult. This surgical procedure often causes large damage to the retinal signal cells that exist in the ILM. Subsequently, more fibrous astrocytes, even RPE cells are liberated into vitreous cavity, forming a denser, more opaque type of ERM, hence MP. MP often has more counter-contracting force toward the vitreous chamber and is more firmly attached to the vitreous cortex. Surgical removal of MP is more likely to preserve more ILM layer. Desatnik et al. [25] reported a young girl with spontaneous separation of an idiopathic ERM with notable good visual recovery; the grading of ERM in this case was MP according to the clinical characteristics. As MP extends over the vitreous humor, a layer of vitreous may be trapped against the ILM. Spontaneous separation of MP could occur with subsequent vitreous separation without damaging the ILM. Therefore, the definite distinction between these two groups is still unclear and requires further investigation, such as histological and electromicroscopic findings, to validate our assumption.

In our series, we used TA during vitrectomy surgery to visualize ERMs and the vitreous and assist peeling surgery. TA is a water-insoluble steroid, allows delineation of ILM and ERM, and does not stain exposed retina, so it aids in peeling surgery without retinal damage. When comparing TA and ICG, TA had less adverse effects than ICG, including RPE defects, long-term retinal staining, optic nerve damage, and photosensitivity to laser energy. Unlike ICG, which requires a specific dilution ratio, TA does not require any preparation in the operating room. ICG, unlike TA, cannot be completely removed from all the tissues in the eye after it is used, as it stains the tissue. Besides, TA is well known for its anti-inflammatory, antifibrotic, anti-permeability, and antiangiogenic properties, which show a decrease in postoperative blood-ocular barrier breakdown and lead to fluid absorption from edematous retinal tissue by both stimulating endogenous adenosine signaling in Müller cells, thereby having a beneficial effect in the treatment of intraocular surgery [26]. Furthermore, TA also appears to have a neuroprotective action on photoreceptors that helps the recovery of retinal function. Konstantinidis et al. [27] have shown that intravitreal TA injection after sutureless vitrectomy and membrane peeling surgery may speed up and improve anatomic and functional outcomes. Several previous studies [28–30] have suggested that TA inhibits some growth factors that would be expressed in glial components of idiopathic ERM.

In conclusion, the present study shows that peeling surgery can lead to a significant reduction of macular edema in idiopathic macular ERM. However, visual improvements are not distinct in simple macular surgery

because of progressive cataract formation. Therefore, the advantages of combined cataract surgery result in achieving maximum final VA. A long-term ERM persistence will cause unrecoverable retinal damage and visual loss. This study also indicated that the classification of MP seems to provide better surgical outcome compared with CM, but the etiology still needs further investigation.

References

- [1] Bouwens MD, de Jong F, Mulder P, van Meurs JC. Results of macular pucker surgery: 1- and 5-year follow-up. *Graefes Arch Clin Exp Ophthalmol* 2008;246:1693–7.
- [2] Pournaras CJ, Donati G, Brazitikos PD, Kapetanios AD, Drekalis DL, Stangos NT. Macular epiretinal membranes. *Semin Ophthalmol* 2000;15:100–7.
- [3] Foos RY. Vitreoretinal juncture; epiretinal membranes and vitreous. *Invest Ophthalmol Vis Sci* 1977;16:416–22.
- [4] Johnson MW. Posterior vitreous detachment: evolution and complications of its early stages. *Am J Ophthalmol* 2010;149:371–82. e371.
- [5] Gass. *Stereoscopic atlas of macular disease*. St Louis, MO: Mosby-Year book; 1987.
- [6] Jacobsen CH. Epiretinal membranes. *Optom Clin* 1996;5:77–94.
- [7] Miller B. Epiretinal macular membranes: pathogenesis and treatment. *Dev Ophthalmol* 1997;29:61–3.
- [8] Alexandrakis G, Chaudhry NA, Flynn Jr HW, Murray TG. Combined cataract surgery, intraocular lens insertion, and vitrectomy in eyes with idiopathic epiretinal membrane. *Ophthalmic Surg Lasers* 1999;30:327–8.
- [9] Koenig SB, Mieler WF, Han DP, Abrams GW. Combined phacoemulsification, pars plana vitrectomy, and posterior chamber intraocular lens insertion. *Arch Ophthalmol* 1992;110:1101–4.
- [10] Jain V, Kar D, Natarajan S, Shome D, Mehta H, Mehta H, et al. Phacoemulsification and pars plana vitrectomy: a combined procedure. *Indian J Ophthalmol* 2007;55:203–6.
- [11] Lahey JM, Francis RR, Fong DS, Kearney JJ, Tanaka S. Combining phacoemulsification with vitrectomy for treatment of macular holes. *Br J Ophthalmol* 2002;86:876–8.
- [12] Senn P, Schipper I, Perren B. Combined pars plana vitrectomy, phacoemulsification, and intraocular lens implantation in the capsular bag: a comparison to vitrectomy and subsequent cataract surgery as a two-step procedure. *Ophthalmic Surg Lasers* 1995;26:420–8.
- [13] Kokame GT, Flynn Jr HW, Blankenship GW. Posterior chamber intraocular lens implantation during diabetic pars plana vitrectomy. *Ophthalmology* 1989;96:603–10.
- [14] de Bustros S, Thompson JT, Michels RG, Enger C, Rice TA, Glaser BM. Nuclear sclerosis after vitrectomy for idiopathic epiretinal membranes. *Am J Ophthalmol* 1988;105:160–4.
- [15] Dugas B, Ouled-Moussa R, Lafontaine PO, Guillaubey A, Berrod JP, Hubert I, et al. Idiopathic epiretinal macular membrane and cataract extraction: combined versus consecutive surgery. *Am J Ophthalmol* 2010;149:302–6.
- [16] Ando A, Nishimura T, Uyama M. Surgical outcome on combined procedures of lens extraction, intraocular lens implantation, and vitrectomy during removal of the epiretinal membrane. *Ophthalmic Surg Lasers* 1998;29:974–9.
- [17] Park DW, Dugel PU, Garda J, Sipperley JO, Thach A, Sneed SR, et al. Macular pucker removal with and without internal limiting membrane peeling: pilot study. *Ophthalmology* 2003;110:62–4.

- [18] Bovey EH, Uffer S, Achache F. Surgery for epimacular membrane: impact of retinal internal limiting membrane removal on functional outcome. *Retina* 2004;24:728–35.
- [19] Sivalingam A, Eagle Jr RC, Duker JS, Brown GC, Benson WE, Annesley Jr WH, et al. Visual prognosis correlated with the presence of internal-limiting membrane in histopathologic specimens obtained from epiretinal membrane surgery. *Ophthalmology* 1990;97:1549–52.
- [20] Snead DR, Cullen N, James S, Poulson AV, Morris AH, Lukaris A, et al. Hyperconvolution of the inner limiting membrane in vitreomaculopathies. *Graefes Arch Clin Exp Ophthalmol* 2004; 242:853–62.
- [21] Snead DR, James S, Snead MP. Pathological changes in the vitreoretinal junction 1: epiretinal membrane formation. *Eye (Lond)* 2008;22:1310–7.
- [22] Gibran SK, Flemming B, Stappler T. Peel and peel again. *Br J Ophthalmol* 2008;92:373–7.
- [23] Terasaki H, Miyake Y, Nomura R, Piao CH, Hori K, Niwa T, et al. Focal macular ERGs in eyes after removal of macular ILM during macular hole surgery. *Invest Ophthalmol Vis Sci* 2001;42:229–34.
- [24] Tari SR, Vidne-Hay O, Greenstein VC, Barile GR, Hood DC, Chang S. Functional and structural measurements for the assessment of internal limiting membrane peeling in idiopathic macular pucker. *Retina* 2007;27:567–72.
- [25] Desatnik H, Treister G, Moisseiev J. Spontaneous separation of an idiopathic macular pucker in a young girl. *Am J Ophthalmol* 1999;127:729–31.
- [26] Couch SM, Bakri SJ. Use of triamcinolone during vitrectomy surgery to visualize membranes and vitreous. *Clin Ophthalmol* 2008;2:891–6.
- [27] Konstantinidis L, Berguiga M, Beknazar E, Wolfensberger TJ. Anatomic and functional outcome after 23-gauge vitrectomy, peeling, and intravitreal triamcinolone for idiopathic macular epiretinal membrane. *Retina* 2009;29:1119–27.
- [28] Matsuda S, Gomi F, Oshima Y, Tohyama M, Tano Y. Vascular endothelial growth factor reduced and connective tissue growth factor induced by triamcinolone in ARPE19 cells under oxidative stress. *Invest Ophthalmol Vis Sci* 2005;46: 1062–8.
- [29] Ebrahim Q, Minamoto A, Hoppe G, Anand-Apte B, Sears JE. Triamcinolone acetonide inhibits IL-6- and VEGF-induced angiogenesis downstream of the IL-6 and VEGF receptors. *Invest Ophthalmol Vis Sci* 2006;47:4935–41.
- [30] Wang YS, Friedrichs U, Eichler W, Hoffmann S, Wiedemann P. Inhibitory effects of triamcinolone acetonide on bFGF-induced migration and tube formation in choroidal microvascular endothelial cells. *Graefes Arch Clin Exp Ophthalmol* 2002;240:42–8.