

CLOSE-WEDGE OSTEOTOMY FOR BONY LOCKING STIFFNESS OF THE ELBOW IN GORHAM DISEASE PATIENTS: A CASE REPORT

Hsien-Chung Wang and Gau-Tyan Lin

Department of Orthopedic Surgery, Chung-Ho Memorial Hospital,
Kaohsiung Medical University, Kaohsiung, Taiwan.

Gorham disease is a so-called massive idiopathic osteolysis or vanishing bone disorder. Massive osteolysis remains an enigmatic condition that involves various skeletal locations and is caused by endothelial proliferation. The diagnosis is difficult and is established via the association of clinical, radiologic and histologic pictures. Treatment modalities yield variable results. We report a case of vanishing bone in the elbow joint and carpal bones following trauma. This 13-year-old boy complained of severe restricted motion and deformity of the right elbow. We managed the problem using arthroplasty with close-wedge osteotomy on the lateral condyle of the humerus.

Key Words: osteotomy, Gorham disease
(*Kaohsiung J Med Sci* 2004;20:250–5)

Disappearing bone disease is a rare disorder characterized by spontaneous resorption of bones with mono- or polyostotic lesions. Since Jackson first described this disease in 1838, approximately 200 cases have been documented in the medical literature under various synonyms, including phantom bone, vanishing bone, disappearing bone, massive osteolysis, and Gorham-Stout syndrome [1]. The disease can occur in any bone and at any age, resulting in skeletal deformity with functional disability [1,2]. Despite the fact that, in 1955, Gorham and Stout proposed the pathologic mechanism of massive osteolysis due to angiomatosis of blood and sometimes of lymphatic vessels, the exact etiology of disappearing bone disorder remains unclear [3]. According to radiologic and histologic findings, idiopathic osteolysis is a different entity from secondary osteolysis

such as malignant, infectious, neuropathic disease. Massive osteolysis is still an enigmatic condition with regard to its clinical course, management, and prognosis. We present a case of vanishing bone of the elbow and bilateral carpus following trauma; treatment consisted of elbow arthroplasty to improve functional disability.

CASE PRESENTATION

A 13-year-old boy first presented in July 2002 with complaints of restricted motion of the right elbow and deformity of the right index finger. Three years earlier, he had suffered a painful disability of his right elbow and wrist following a fall onto his outstretched hands while running. Under the impression of a fracture-dislocation of the right elbow, he was treated by his physician using an immobilizing cast for 2 months.

Recently, progressively decreasing motion had been noted not only in his right elbow, but also in his right wrist. In addition, the right index finger had a radial deformity on the proximal interphalangeal joint. Other physical examina-

Received: November 14, 2003 Accepted: February 25, 2004
Address correspondence and reprint requests to: Dr. Gau-Tyan Lin,
Department of Orthopedic Surgery, Kaohsiung Medical University,
100 Tzyou 1st Road, Kaohsiung, Taiwan.
E-mail: gtlin@kmu.edu.tw

tions, including skin appearance and ocular problems, were within normal ranges. Radiographic study demonstrated that the bilateral carpal bones were vanishing; the left second to fifth metacarpal bones presented a “sucked candy” appearance (Figure 1A), and the medial condylar of the right humerus had disappeared (Figure 1B). However, radiologic examination of the lateral condyle of the right humerus showed a picture of bony enlargement, which interfered with elbow flexion and extension. Laboratory investigations, including those for renal function, thyroid function, and infection, were within normal ranges. His parents stated that no members of his family had an illness resembling his. The birth and development history were non-contributory. Elbow flexion was locked by the enlarged humeral lateral condyle and the cartilage was damaged in both the radial head and capitulum.

He underwent close-wedge osteotomy on the lateral condyle of the right humerus (Figure 2). Histopathologic examination of tissue obtained from the osteotomy area showed that bone tissue had been replaced by fibrous tissue containing many thin-walled vessels and small or large vascular spaces; focal bone necrosis was noted (Figure 3). The clinical, radiographic, and histopathologic features supported a diagnosis of vanishing bone disease. Two months later, radiographic study revealed a healed osteotomy and no further bone absorption. Although postoperative convalescence was smooth, the patient performed a heavy stretching and exercise regimen, resulting in a right humeral supracondylar fracture 3 months after surgery. After 10 months’ follow-up, there was a sound union of the humeral supracondylar fracture (Figure 4). The patient’s

right elbow had a flexion arc of 60° compared with only 10° preoperatively.

DISCUSSION

Massive osteolysis is a rare radiologic finding, and is different from idiopathic and secondary resorption of bone, which are associated with diseases such as infection, trauma, and neoplasm. According to Torg et al’s 1969 classification of idiopathic osteolysis [4], there are five types obtained by first dividing according to hereditary into sportic, and then subdivided into multicentric or monocentric. Type 1 is hereditary multicentric osteolysis with dominant transmission. Type 2 is similar to Type 1, but with recessive transmission. Type 3 is nonhereditary multicentric osteolysis associated with nephropathy, and Type 4 is Gorham-Stout’s syndrome. Type 5 is Winchester syndrome, which is characterized by carpotarsal osteolysis and skin lesions in childhood. The approach to Gorham osteolysis is based on the exclusion principle using clinical, radiologic, and histopathologic features.

The natural course of Gorham osteolysis is generally unpredictable. Most cases are benign with spontaneous arrest in the few years after osteolysis [3,5]. This disease is usually reported in the second or third decade of life, and is not predicated on gender or race [6]. The initial clinical complaint is substantial pain or soft-tissue swelling, which frequently follows trauma. Then, local progressive and spontaneous resorption of bone in multiple focal or unifocal areas results in functional disability and deformity or even

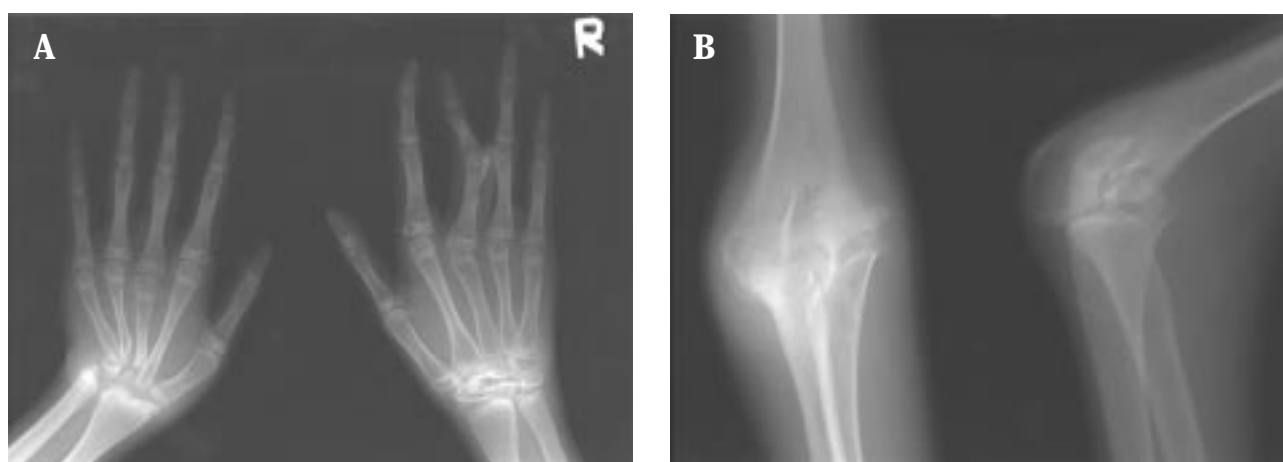

Figure 1. (A) Radiograph of both hands shows vanishing carpal bones and tapering left second to fifth metacarpal bones. (B) Radiograph of the right elbow showing the absence of the medial condyle and relative enlargement of the lateral condyle.

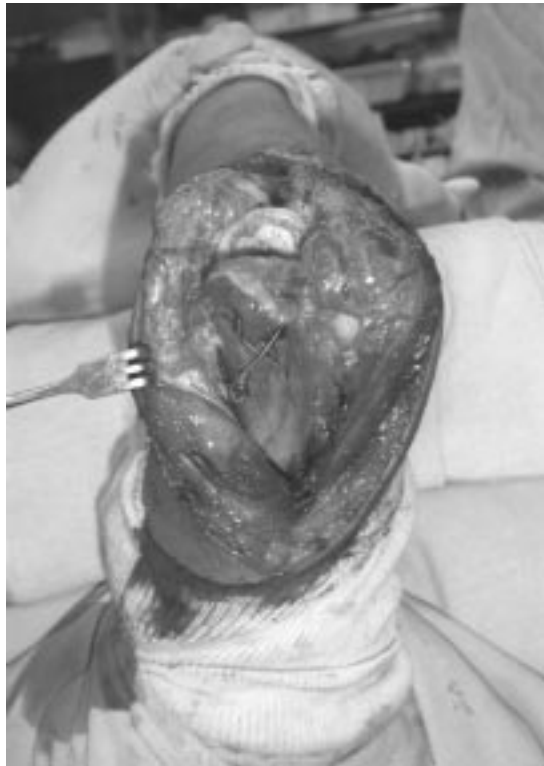

Figure 2. Intraoperative photograph showing close-wedge osteotomy of the lateral condyle of the right humerus using a posterior triceps sparing approach.

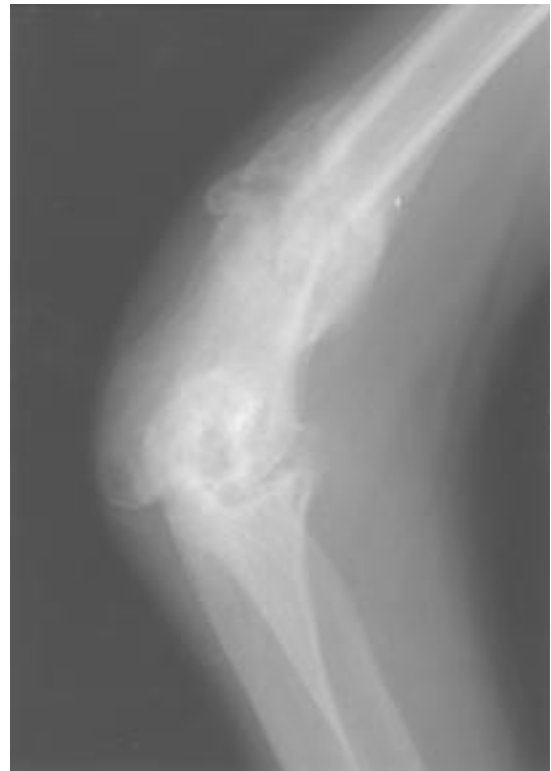

Figure 4. After 10 months' follow-up, radiograph of the right elbow shows healing of the fracture site and no further bone absorption.

pathologic fracture [5]. The potentially fatal complications include spine involvement and pleural effusion. Progressive osteolysis of the spine may lead to paraplegia, and recurrent pleural effusion may cause infection as well as cardiovascu-

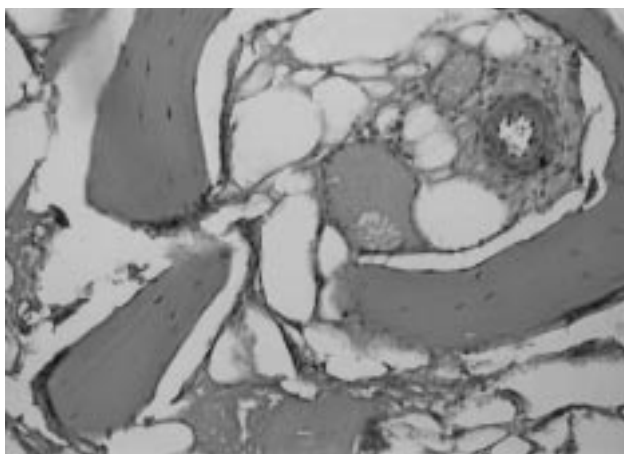


Figure 3. Photomicrograph showing that bone tissues are replaced by fibrous tissue containing many thin-walled vessels and small or large vascular spaces; there is focal bone necrosis (hematoxylin & eosin, $\times 40$).

lar failure. Results of laboratory analysis are usually normal, except that the erythrocyte sedimentation rate is elevated and alkaline phosphatase is occasionally elevated with associated fractures.

Roentgenographic study with several imaging modalities is the most convenient and noninvasive diagnostic tool. Johnson and McClure demonstrated that this radiographic process of massive osteolysis has two stages [2]. The early intraosseous stage is characterized by "patchy" osteoporosis with multiple intramedullary and subcortical radiolucent foci. The later extraosseous stage demonstrates a combination of the onset of cortical erosion and local soft-tissue involvement followed by the "disappearance" of most of the remainder of the bone with the typical sucked candy stick picture. Many other imaging modalities, such as angiography, venography, and lymphangiography, have been used to reveal the pathologic vascular process inside the involved bone [2,7]. In 1997, Spieth et al used a three-phase bone scan to demonstrate the role of osteoclasts in bone resorption in Gorham's disease [8]. Only computerized tomography-guided intraosseous angiography is an effective imaging modality for demonstrating

the angiomatous structures in the involved area [7]. The extent of disease and presence of a space-occupying mass are easily diagnosed using magnetic resonance imaging. However, it is hard to achieve a correct diagnosis with these imaging modalities.

Although the mechanism of massive osteolysis remains unclear, the presence of numerous thin-walled vessels lined by endothelial cells and the appearance of loose angiomatosis-like granulation tissue are routine pathologic findings. In 1955, Gorham and Stout reported that this progressive osteolysis was always associated with angiomatosis of blood vessels and sometimes of lymphatic vessels [3]. Thompson and Schurman suggest that unrestricted growth of granulation tissue exerts pressure, resulting in bone resorption [9]. Recently, Cannon maintained that active osteoclastic resorption was associated with vascular dilatation [10]. Other recent studies suggest that the hyperactive osteoclastic bone resorption is the result of osteolytic changes, and that anti-resorptive therapy, such as bisphosphonates or calcitonin, is a reasonable treatment for progressive osteolysis [1,7,10]. The regulation of osteoclasts in massive osteolysis is influenced by autocrine and paracrine factors to express the different osteolytic phases. Study of differential gene and proto-oncogene expression in osteoclasts has provided a clear explanation of the pathogenesis of massive osteolysis [1,11].

In 1983, Heffez et al suggested eight criteria for distinguishing Gorham disease from other diseases with bone destruction [12]: biopsy positive for angiomatous tissue; absence of cellular atypia; minimal or no osteoblastic response and no dystrophic calcification; evidence of local progressive osseous resorption; non-expansile, non-ulcerative lesions; no visceral involvement; osteolytic radiographic pattern; and no hereditary, metabolic, neoplastic, immunologic, or infectious etiology. The clinical presentation in our patient did not indicate an infectious, neoplastic, endocrine, metabolic, or neuromuscular disease. Furthermore, the radiologic picture was characterized by a vanishing bone pattern. After the confirmation of histologic evidence, the presentation was entirely consistent with Gorham disease.

Various therapies have been tried, but successful results have been reported in only a few cases. Most medical treatments, such as hormones, vitamins, calcium salts, chemotherapy, and transfusion of placental blood, are unable to stop the disease process [1]. A review of the literature suggests that early radiation therapy with a dose of 30 to 40 Gy is an efficient method to stop disease progression [13,14]. Despite this, the osteolytic process usually under-

goes spontaneous arrest. The disease results in residual deformity or functional disability and, sometimes, mortality. Several surgical options have been provided to resolve these complications. Resection with endoprosthesis is effective, but resection with bone grafting often fails [6,15,16].

In this patient, we excised a bony wedge of the lateral humeral condyle to obtain a histologic diagnosis, and then reconstructed a new elbow joint to recover the normal functional arc. After 10 months' follow-up, his right elbow had not achieved a functional demand arc of 100°, but he could flex more than half of the functional arc. The patient and his parents are satisfied with this clinical outcome. The rationale for consolidation of fracture and osteotomy may be in the timing, since the disease underwent spontaneous arrest. Even given the lack of long-term evidence to reveal the complete arrest of bony absorption, we still recommend that reconstruction of the deformity using wedge osteotomy be an alternative to amputation in Gorham disease.

REFERENCES

1. Moller G, Priemel M, Amling M, et al. The Gorham-Stout syndrome (Gorham's massive osteolysis): a report of six cases with histopathological findings. *J Bone Joint Surg Br* 1999;81: 501-6.
2. Johnson PM, McClure JG. Observations of massive osteolysis: a review of the literature and report of a case. *Radiology* 1958; 71:28-42.
3. Gorham LW, Stout AP. Massive osteolysis (acute spontaneous absorption of bone, phantom bone, disappearing bone): its relation to hemangiomas. *J Bone Joint Surg Am* 1955;37: 985-1004.
4. Torg JS, DiGeorge AM, Kirkpatrick JA Jr, et al. Hereditary multicentric osteolysis with recessive transmission: a new syndrome. *J Pediatr* 1969;75:243-53.
5. Tauro B. Multicentric Gorham's disease. *J Bone Joint Surg Br* 1992;74:928-9.
6. Kulenkampff HA, Richter GM, Hasse WE, et al. Massive pelvic osteolysis in the Gorham-Stout syndrome. *Int Orthop* 1990;14:361-6.
7. Hayden G, Kindblom LG, Nielsen JM. Disappearing bone disease: a clinical and histological study. *J Bone Joint Surg Am* 1977;59:57-61.
8. Spieth ME, Greenspan A, Forrester DM, et al. Gorham's disease of the radius: radiographic, scintigraphic, and MRI finding with pathologic correlation. A case report and review of the literature. *Skeletal Radiol* 1997;26:659-63.
9. Thompson JS, Schurman DJ. Massive osteolysis: case report and review of the literature. *Clin Orthop* 1974;103:206-11.
10. Cannon SR. Massive osteolysis: a review of seven cases. *J Bone Joint Surg Br* 1986;68:24-8.
11. Tanaka S, Amling M, Neff L, et al. c-Cbl is downstream of c-Src in a signaling pathway necessary for bone resorption.

- Nature* 1996;383:528–31.
12. Heffez L, Doku HC, Carter BL, Feeney JE. Perspectives on massive osteolysis. Report of a case and review of the literature. *Oral Surg Oral Med Oral Pathol* 1983;55:331–43.
 13. Dunbar SF, Rosenberg A, Mankin H, et al. Gorham's massive osteolysis: the role of radiation therapy and a review of the literature. *Int J Radiat Oncol Biol Phys* 1993;26:491–7.
 14. Shives TC, Beabout JW, Unni KK. Massive osteolysis. *Clin Orthop* 1993;294:267–76.
 15. Woodward HR, Chan DP, Lee J. Massive osteolysis of the cervical spine: a case report of bone graft failure. *Spine* 1981;6:545–9.
 16. Choma ND, Biscotti CV, Bauer TW, et al. Gorham's disease: a case report and review of the literature. *Am J Med* 1987;83:1151–6.

封閉契形切骨術治療戈罕氏病患 手肘骨性閉鎖僵硬 — 病例報告

王憲忠 林高田

高雄醫學大學附設中和紀念醫院 骨科

戈罕氏病是一所謂大量自發溶骨性疾病或消失的骨疾病。大量自發溶骨性疾病是否由內皮增生造成與侵犯骨骼各處的情形仍是一團謎。診斷困難並且是建立在臨床與影像及組織上的表現之相關性。各種治療方法有各式各樣的結果。吾人報告一個在創傷後肘部與掌骨骨頭消失的病例。這個十三歲男孩抱怨右手肘活動受限與變形。我們提出在肱骨外髁處施行封閉契形切骨作關節整形術來解決這個問題。

關鍵詞：封閉契形切骨術，戈罕氏病

(高雄醫誌 2004;20:250-5)

收文日期：92年11月14日

接受刊載：93年2月25日

抽印本索取處：林高田醫師

高雄醫學大學附設中和紀念醫院骨科

高雄市自由一路100號