

# PERCUTANEOUS RELEASE FOR TRIGGER THUMB IN CHILDREN UNDER GENERAL AND LOCAL ANESTHESIA

Hsien-Chung Wang and Gau-Tyan Lin

Department of Orthopedic Surgery, Chung-Ho Memorial Hospital,  
Kaohsiung Medical University, Kaohsiung, Taiwan.

A retrospective trial of percutaneous release for 40 trigger thumbs in 33 children under different types of anesthesia (general versus local) at a mean age of 2.5 years was conducted between February 1989 and March 2003. Based on the tolerance of the child and parents, 20 children were processed using local anesthesia at our office and 13 children were given general anesthesia. We recommend special manipulation to ensure complete release of the A1 pulley when general anesthesia is necessary. Of the 26 trigger thumbs in the local anesthesia group, 23 were successfully released. Only one patient in the general anesthesia group had an unsatisfactory outcome. Percutaneous surgery achieved a 90% successful release rate for trigger thumb in children, without recurrence. There was no statistical difference in the release of trigger thumbs with these two anesthetic procedures ( $p = 0.66$ ). Overall, 37 trigger thumbs achieved full extension and flexion without any residual deformity following percutaneous release. Our results suggest that percutaneous release for trigger thumb is satisfactory, no matter which method of anesthesia is used.

**Key Words:** percutaneous release, trigger thumb, local anesthesia, general anesthesia  
(*Kaohsiung J Med Sci* 2004;20:546–51)

Trigger thumb or stenosing tendovaginitis of the flexor pollicis longus tendon is relatively uncommon in children. Its etiology is still a matter of controversy. Three possible causes have been suggested. Several authors have proposed a congenital or hereditary cause [1–5], while others suggest that it is the result of trauma, when it is easily misdiagnosed as a fracture of the thumb or a dislocation of the interphalangeal joint [6,7]. Slakey and Hennrikus suggest that it is an “acquired thumb flexion contracture in children” [8]. Clinically, trigger thumb usually presents with a fixed contracture and a palpable nodule. Trigger and pain are not common [7,9].

The traditional treatment of trigger thumb in children, when conservative treatment has failed, is surgical release. In 1974, Dinham and Meggitt showed that congenital trigger thumb resolves spontaneously in 30% of patients diagnosed from birth to the age of 6 months and in 12% of those diagnosed between 6 and 30 months [6]; if the patient is diagnosed from the age of 3 years, they suggested surgical release. Recent studies suggest that conservative treatment may be used, and that surgery can achieve full correction of the flexion contracture even after the age of 3 years [10–12]. In Japan, treatments with splinting have been reported to show satisfactory results [13,14].

In 1992, Eastwood et al proposed percutaneous release as an office procedure for management of adult trigger digits [15]. The main advantages of this procedure are that there is no need for admission or an operating room, and that it easily and quickly achieves its outcome. The aims of this study were to demonstrate the convenience of this office procedure for trigger thumb in children and to show that it can achieve a similar outcome to that in adult trigger digits. As any surgical intervention in children can be

Received: June 3, 2004

Accepted: October 4, 2004

Address correspondence and reprint requests to: Dr. Gau-Tyan Lin, Department of Orthopedic Surgery, Chung-Ho Memorial Hospital, Kaohsiung Medical University, 100 Tzyou 1<sup>st</sup> Road, Kaohsiung 807, Taiwan.

E-mail: gtlm@kmu.edu.tw

harmful and unpredictable, applying this office procedure under local anesthesia is difficult. If the parents could not tolerate the crying and struggling of their children or we encountered uncooperative patients, we administered general anesthesia. However, it is difficult to confirm whether the release is complete under general anesthesia, due to the loss of the snapping reference point during active flexion and extension. Thus, we used a manipulation method to ensure complete release of the A1 pulley whenever general anesthesia was necessary for sensitive children and their parents.

## MATERIALS AND METHODS

We carried out a retrospective study in 33 children (40 thumbs) who presented with trigger thumb between February 1989 and March 2003. All children were treated using surgical release without prior splinting. We reviewed their medical records, noting the age at the time of presentation, age at onset of triggering, presence of a palpable mass (Notta's node), and presence of a fixed flexion contracture. Their surgical records were reviewed for anesthetic type, surgical treatment, surgical timing, and condition of the flexor tendons.

All patients were assessed by their parents and the authors to determine outcome and recurrence. Postoperative data were reviewed, including the presence or absence of trigger thumb, recovery of range of motion, lack of flexion contracture, and complications such as infection or sensory deficit. We assessed digital nerve function using the sensor response to light touch and prick pain on the ulnar and radial sides of the involved thumb, and compared the difference from other fingers that were examined by other authors, when patients could express this well, generally at the age of more than 3 years. A satisfactory result indicated no triggering and normal range of motion on physical examination, while a residual trigger or decreased range of motion indicated an unsatisfactory result.

We performed percutaneous release on the trigger thumbs of children using two different anesthetic procedures, general or local anesthesia. Local anesthesia was achieved using 1 mL of 2% xylocaine to block digit nerves. In our office, the patient underwent the release procedure 5 minutes after digital block (Figure 1). In the group receiving general anesthesia, we used two methods: intravenous agents such as thiamylal sodium (Citosol<sup>®</sup>; Kyorin Pharmaceutical Co Ltd, Tokyo, Japan), fentanyl citrate (Dura-gesic<sup>®</sup>; Janssen Pharmaceutica, Titusville, NJ, USA) and



**Figure 1.** Percutaneous release under local anesthesia for trigger thumb in children as an office procedure.

ketamine hydrochloride (Ketalar<sup>®</sup>; Pfizer Inc, New York, NY, USA); or mask ventilation with sevoflurane (Ultane<sup>®</sup>; Abbott Laboratories Ltd, Abbott Park, IL, USA). After surgery, the children returned home without hospitalization.

The Chi-squared test was used to analyze differences between anesthesia procedures.

### *Percutaneous release*

All patients underwent percutaneous release for their trigger thumbs, performed by the same surgeon (GTL) [16]. The affected thumb was placed in extension, and a 19 gauge hypodermic needle was inserted to the proper depth of the flexor sheath at the level of the A1 pulley. The thumb was semiflexed to loosen the palmar skin, allowing easier movement of the needle. We moved the needle longitudinally and parallel to cut the flexor tendon sheath, rather than with a pivot maneuver [17]. As the thumb carries the greatest potential for nerve injury during surgery, the entry point was usually located at the skin crease of the metacarpal joint and never deviated too radically. We ensured that the A1 flexor tendon sheath was completely released and active motion of the affected thumb showed no residual triggering. Lastly, compression was applied for at least 10 minutes for homeostasis to prevent postoperative hematoma and swelling.

### *Manipulation technique for percutaneous release under general anesthesia*

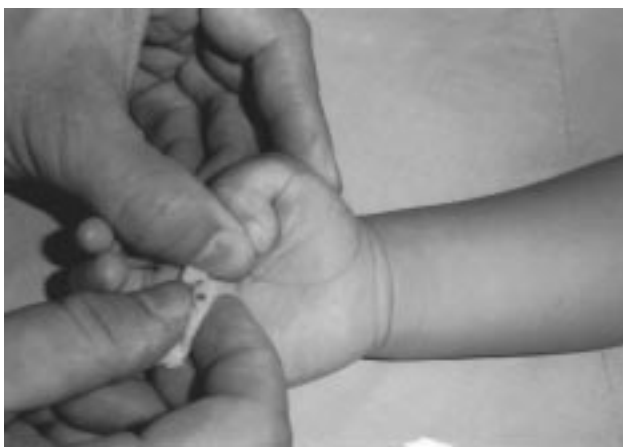The senior author (GTL) developed a special manipulation technique to ensure complete release of the A1 pulley in cases performed via percutaneous surgery under general anesthesia. The thumb was passively flexed by pushing

back the hypertrophied nodule of the flexor tendon crossing over the A1 pulley, then the thumb was extended (Figure 2). If the A1 pulley is not completely released, snapping will reappear. The surgeon repeated the above needle bevel maneuver until the A1 pulley was completely released.

**RESULTS**

The 33 patients with 40 trigger thumbs were aged less than 9 years, with a mean age of 2.5 years. They included 19 male (57.6%) and 14 female (42.4%) patients, giving a slight male preponderance. Seven patients (21.2%), three girls and four boys, had bilateral lesions. In the 26 cases of unilateral trigger thumb, 18 children had affected thumbs on the right side (69.2%) and eight had affected thumbs on the left side (30.8%) (Table 1). Right dominant thumbs were mainly affected. The mean age at onset of trigger thumb was 2.4 years; 10 trigger thumbs were found at the age of less than 6 months. The age at which trigger thumb release was performed ranged from 10 months to 8 years 9 months, with an average age of 2.5 years (Figure 3). All patients were assessed for at least 16 months after surgery, with an average follow-up time of 4.7 years (range, 16 months to 13 years and 1 month).

In our patients, the symptoms of affected thumbs were primarily fixed flexion contracture, Notta’s node, and pain. Other presentations, including active extension loss, trigger or snap, were sometimes hard to approach due to the young age of these children. Three children had clear trauma events:



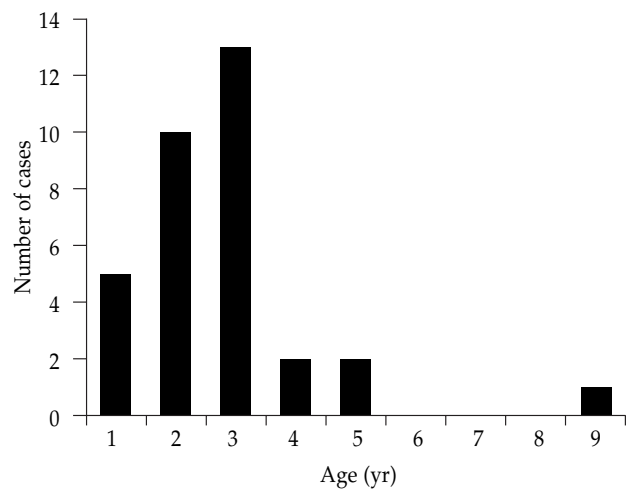
**Figure 2.** Special manipulation under general anesthesia to assess complete release of the A1 pulley. The thumb is flexed as the nodule of the flexor tendon crossing over the A1 pulley is pushed back, then the thumb is extended. If the A1 pulley is not completely released, snapping will appear again during this maneuver.

**Table 1.** Number of patients and affected thumbs undergoing percutaneous release under local (LA) and general anesthesia (GA)

	LA, n	GA, n	Total, n (%)
Bilateral cases	4	3	7 (21.2)
Girls	2	1	3 (9.1)
Boys	2	2	4 (12.1)
Unilateral cases	16	10	26 (78.8)
Girls	10	1	11 (33.3)
Boys	6	9	15 (45.5)
Subtotal no. of patients	20	13	33
Subtotal no. of thumbs	24	16	40

a slipped fall, a “slammed door injury”, and a fall from bed. The other children’s injuries were of unknown origin. During the follow-up period, no cases revealed postoperative complications (except postoperative pain for 1–4 days). There was no sensory deficit and no nerve injury. Of the 40 thumbs, 36 exhibited a satisfactory outcome. All of these patients could grasp with full strength, comparable to an unaffected thumb, and no bowstring phenomena were observed.

The method of anesthesia was dependent on the tolerance of the child and its parents, and the judgment of the doctors. Twenty children were managed under local anesthesia (60.6%) and 13 under general anesthesia (39.4%) (Table 1). In 93% of patients receiving general anesthesia and 89% of those receiving local anesthesia, the children and parents were satisfied with the results. There was no statistical difference in the outcome of percutaneous release



**Figure 3.** Age at which trigger thumb release was performed.

in patients receiving general or local anesthesia ( $p = 0.66$ ) (Table 2). No children had had recurrence at the final interview.

Only four unsatisfactory results were noted in our study. One 3-year-old boy had acquired trigger thumb with a 1-year course. He initially underwent percutaneous release under general anesthesia. His parents found a residual deformity after surgery and he underwent the same procedure under local anesthesia 3 days later. He had full active extension at the 3-month follow-up. A girl aged 2.6 years underwent percutaneous release under local anesthesia. During surgery, we found the A1 pulley to be quite thick and long, and hard to release completely with a needle. The problem was resolved using open release. Another two girls, aged 1 year and 3.25 years, respectively, had unsatisfactory results under local anesthesia. They suddenly feared the operative course and would not cooperate during the office procedure, so we were unable to check whether the release was complete. Both parents and patients refused further management and the thumbs have residual deformity.

## DISCUSSION

Most articles reveal a nearly equal distribution of gender and dominant affected side [6,9,17,18]. However, our study shows a male and right-thumb preponderance. The age at which release was performed was between 2 and 3 years in most cases. These results are compatible with recent studies [9,11,13,19]. The distribution of the age of onset of trigger thumb was 25% at less than 6 months in our cases. Our data do not agree with current studies with regard to acquired origin [8,9]. These authors believe the incidence is less than three in 1,000 newborns, and that trigger thumb does not affect the grasp of newborns. Since our sample size was not sufficiently large, we were unable to draw any conclusions as to whether the etiology is congenital or acquired.

**Table 2.** Results of percutaneous release of trigger thumb following local (LA) and general anesthesia (GA) ( $p = 0.66$ )

	Number of thumbs, <i>n</i> (%)		Total <i>n</i> (%)
	LA	GA	
Satisfactory	23 (88.5)	13 (92.9)	36 (90.0)
Unsatisfactory	3 (11.5)	1 (7.1)	4 (10.0)
Total	26	14	40

Notta observed percutaneous release in trigger fingers as early as 1850. Recently, many authors have reported that percutaneous release is a simple office procedure with few complications [15,16,20]; the procedure is convenient and can be performed without expensive equipment. Many orthopedists use it to treat adult trigger digits. However, this percutaneous surgery can damage neurovascular structures without direct visualization. In addition, it requires a learning curve to achieve complete correction with no harm to other tissues. We applied this procedure to the treatment of trigger thumb in children. We originally intended to perform the procedure under local anesthesia rather than general anesthesia, to achieve the benefit of convenience. However, any surgical procedure performed in children is a traumatic event for themselves and their parents. Dividing patients into local and general anesthesia groups demonstrated the possibility of using local anesthesia in young children. For sensitive children and parents, percutaneous release under general anesthesia is another option.

In the literature, complications of percutaneous release resulting in injury to digital nerves in adult trigger digits are rarely reported [15,20]. During the follow-up period, all the patients in our study had smooth postoperative convalescence, except for wound pain. As most young children are unable to clearly express themselves about an injury to the digital nerve or vessel, we relied on the observations of their parents and clinical examinations of thumb sensations until they were able to better express themselves (generally at the age of 3 years). There are several reasons for the low complication rates following this percutaneous technique. A needle has a relatively small depth and blade area compared with a knife [16], and the smaller wound made by a needle is less susceptible to complications. Moving the needle to cut the A1 pulley must be a longitudinal and parallel maneuver, not a pivot maneuver. In addition, an experienced surgeon who understands the anatomy of the A1 pulley of the flexor hallucis longus and variants of digital nerves performed the percutaneous releases [16,21]. It is also important that we used compression for at least 10 minutes to avoid subcutaneous hematoma and, thus, prophylactic antibiotics were unnecessary.

The difficulty of the percutaneous release technique under local anesthesia is cooperation from the patient and parents, as well as the fact that the parents cannot tolerate the crying and struggling of the child. In fact, children aged between 2 and 2.5 years find it easier to accept the procedure under local anesthesia than others. Older children tend to fear white-coated doctors. For younger children, though, their parents care very much about any procedure that

causes them to suffer. The main problem of the percutaneous release technique under general anesthesia is that we lose the reference point to check whether there is complete release, since patients lose active flexion under general anesthesia. We need the convenient manipulation to ensure complete release of the A1 pulley.

In this study, patients and parents were satisfied with the final result in 36 of 40 thumbs (90%) following the percutaneous release. There was no significant difference between satisfactory results with local (89%) and general anesthesia (94%;  $p = 0.66$ ). In other words, these two different anesthesia methods did not affect the result of percutaneous release. In contrast to other non-invasive methods for treating trigger thumb in children, the success rate of splinting is about 90%, but it takes a long time and yields better results in younger children [5,13]. Mulpruek and Prichasuk suggest that spontaneous recovery of trigger thumb in children is possible, and delaying the operation until after the age of 3 years will not affect the final outcome of surgical release [11]. Most authors agree that spontaneous recovery is superior, but it needs at least 6 months of observation [6,11,18]. However, in 1999, Dunsmuir and Sherlock suggested that the management of trigger thumb in children should proceed directly to surgery and a conservative approach should be abandoned [10]. They note that open surgical release is a quick, effective procedure with rare complications [10,19]. In our country, many parents are worried about the uncertain result during the period of conservative treatment, even after a thorough explanation. Thus, we developed this simple and less invasive method to solve such problems and provide an alternative to open release. The procedure yielded satisfactory results in up to 90% of patients in our study, as high as that of open surgery in other studies [6,8,10,11,18].

Among the cases with unsatisfactory results, the boy with poor outcome under general anesthesia was treated early in our learning curve when we were developing this method. In the local anesthesia group, the two uncooperative cases helped us to learn that the key step to success of complete correction of trigger thumb is the compliance of the patient and the tolerance of the parents. Most patients in the local anesthesia group struggled slightly, comparable to setting the intravenous line during the injection of xylocaine.

Therefore, we conclude that percutaneous release is a simple office procedure to treat trigger thumb in children, with significantly satisfactory results under local anesthesia. We suggest that the release be performed under general anesthesia if children and their parents are very sensitive or have low tolerance. The results under general anesthesia

are satisfactory and similar to those under local anesthesia. Surgeons performing this percutaneous surgery need a learning curve, and must be familiar with the variation in anatomy to avoid nerve complications.

## REFERENCES

1. Gharib R. Stenosing tenovaginitis (trigger finger). *J Pediatr* 1966;69:294-5.
2. Van Genechten F. Familial trigger thumb in children. *Hand* 1982;14:56-8.
3. Weber PC. Trigger thumb in successive generations of a family. A case report. *Clin Orthop* 1979;143:167.
4. White JW, Jensen WE. Trigger thumb in infants. *Am J Dis Child* 1953;85:141-5.
5. Zadek I. Stenosing tenovaginitis of the thumb in infants. *J Bone Joint Surg* 1942;14:326-8.
6. Dinham JM, Meggitt DF. Trigger thumbs in children: a review of the natural history and indications for treatment in 105 patients. *J Bone Joint Surg Br* 1974;56:153-5.
7. Eyres KS, McLaren MI. Trigger thumb in children: results of surgical correction. *J R Coll Surg Edinb* 1991;36:197-8.
8. Slakey JB, Hennrikus WL. Acquired thumb flexion contracture in children: congenital trigger thumb. *J Bone Joint Surg Br* 1996;78:481-3.
9. Rodgers WB, Waters PM. Incidence of trigger digits in newborns. *J Hand Surg Am* 1994;19:364-8.
10. Dunsmuir RA, Sherlock DA. The outcome of treatment of trigger thumb in children. *J Bone Joint Surg Br* 2000;82:736-8.
11. Mulpruek P, Prichasuk S. Spontaneous recovery of trigger thumbs in children. *J Hand Surg Br* 1998;23:255-7.
12. Skov O, Bach A, Hammer A. Trigger thumbs in children: a follow-up study of 37 children below 15 years of age. *J Hand Surg Br* 1990;15:466-7.
13. Nemoto K, Nemoto T, Terada N, et al. Splint therapy for trigger thumb and finger in children. *J Hand Surg Br* 1996;21:416-8.
14. Yuichi T, Koichi T, Hideo K. Splint therapy for trigger finger in children. *Arch Phys Med Rehabil* 1983;64:75-6.
15. Eastwood DM, Gupta KJ, Johnson DP. Percutaneous release of the trigger finger: an office procedure. *J Hand Surg Am* 1992;17:114-7.
16. Lin GT, Chien SH, Hu HT, et al. Percutaneous trigger finger release. *J Orthop Surg ROC* 1997;14:23-8.
17. Fahey JJ, Bollinger JA. Trigger-finger in adults and children. *J Bone Joint Surg Am* 1954;36:1200-18.
18. Ger E, Kupcha P, Ger D. The management of trigger thumb in children. *J Hand Surg Am* 1991;16:944-7.
19. Paaske BP, Soe-Nielsen NH, Noer HH. Release of trigger finger in children. Long term results. *Scand J Plast Reconstr Surg Hand Surg* 1995;29:65-7.
20. Gilberts EC, Beekman WH, Stevens HJ, et al. Prospective randomized trial of open versus percutaneous surgery for trigger digits. *J Hand Surg Am* 2001;26:497-500.
21. Lin GT, Amadio PC, An KN, et al. Functional anatomy of human flexor pulley system. *J Hand Surg Am* 1989;14:949-56.

# 在全身麻醉及局部麻醉下經皮解離兒童的扳機拇指

王憲忠 林高田

高雄醫學大學附設中和紀念醫院 骨科

一追蹤自 1989 年二月至 2003 年三月，有三十三位平均 2.5 歲的兒童之四十隻扳機拇指，在不同麻醉方法 (全身麻醉及局部麻醉) 下，實施經皮解離手術治療的回溯性研究。依孩童及其父母的忍受度，有二十個兒童門診時在局部麻醉下施行經皮解離手術。其他十三位孩童在全身麻醉下施行手術。當比較敏感的孩童及其父母必須實行全身麻醉時，我們推薦一特殊手法來確定 A1 滑車是否解離完全。在局部麻醉組中共有 26 隻扳機拇指，其中有 23 隻成功解離。在全身麻醉組中，只有一個案例是不滿意的結果。經皮手術成功解離兒童的扳機拇指高達 90%。並且沒有復發的案例。經皮解離手術治療扳機拇指在不同麻醉方法下並沒有統計上的差異 ( $p = 0.66$ )。37 隻扳機拇指在經皮解離手術後均能達到完全的主動伸直及主動屈曲，並且沒有遺留任何的畸形。我們的結果顯示不論何種麻醉下經皮解離手術治療兒童的扳機拇指有令人滿意的結果。

**關鍵詞：**經皮解離，扳機拇指，局部麻醉，全身麻醉  
(高雄醫誌 2004;20:546–51)

收文日期：93 年 6 月 3 日

接受刊載：93 年 10 月 4 日

通訊作者：林高田醫師

高雄醫學大學附設中和紀念醫院骨科

高雄市自由一路 100 號