

TOOTH MORPHOMETRY IN LINGUAL ORTHODONTICS

Yu-Chuan Tseng, Hong-Po Chang,¹ and Tsau-Mau Chou¹

Department of Orthodontics, Kaohsiung Medical University Hospital,
and ¹College of Dental Medicine, Kaohsiung Medical University, Kaohsiung, Taiwan.

Lingual orthodontics is used clinically. This study investigated the lingual crown angulation and inclination of optimal occlusion in Taiwanese people. The sample included 45 sets of dental study casts from 28 males and 17 females with optimal occlusion selected from approximately 5,000 young adults. Mesial tipping occurred in all teeth except the upper second molars, the lower central incisors, and the lower lateral incisors. The greatest mesial tipping was observed in the lower second molars. The greatest distal tipping was observed in the lower lateral incisors. Labial (buccal) inclination was observed in all teeth except the lower first molars and the lower second molars. Maximum labial inclination occurred in the upper central incisors. Maximum lingual inclination was observed in the lower first molars.

Key Words: lingual orthodontics, lingual crown angulation, lingual crown inclination
(*Kaohsiung J Med Sci* 2004;20:586–90)

The objectives of orthodontic treatment are to obtain functional occlusion, acceptable esthetics, stability, and healthy oral tissues [1]. One of the criteria for obtaining functional occlusion is ideal axial inclinations for all teeth at the end of active treatment [2]. Thus, selection of proper brackets and arch-wires is important in clinical orthodontics. Pre-adjusted appliances have been developed to control tooth positions in three planes [3].

Lingual orthodontics has been used clinically for more than 20 years [4,5]. However, clinical application of lingual orthodontics and evaluation of treatment results are somewhat difficult due to a lack of orthodontic data on lingual tooth morphology in Taiwanese people. The purpose of this study was to investigate lingual crown angulations and inclinations in optimal occlusion in Taiwanese people.

MATERIALS AND METHODS

The sample consisted of 45 sets of dental study casts from 28 males and 17 females with optimal occlusion selected from

approximately 5,000 young adults aged 16–25 years. To measure lingual surface angles, the occlusal plane was transferred to the cast base with the help of a model set-up (Figure 1). The occlusal plane was determined from the incisal edge of the upper central incisors and the distobuccal cusp tips of the upper first molars. The reference plane was the basal plane of the study cast, which is parallel to the occlusal plane [6–8]. Lingual angulations and inclinations were based on tracings of the lingual axis of the clinical crown (LACC) on a Nikon V-10 profile projector (Nikon, Tokyo, Japan). All measurements were made by one




Figure 1. Standardization of the basal plane of the study cast.

Received: August 23, 2004

Accepted: November 17, 2004

Address correspondence and reprint requests to: Dr. Hong-Po Chang, College of Dental Medicine, Kaohsiung Medical University, 100 Shih-Chuan 1st Road, Kaohsiung 807, Taiwan.

E-mail: hopoch@kmu.edu.tw

investigator to minimize errors in locating the crown axis. We used a lingual trimmer (Dentpia, Tokyo, Japan) to reduce the lingual portion of the dental cast and a CM parallelometer (Cendres & Metaux SA, Biel-Bienne, Switzerland) and milling machine to separate the tooth block. The LACCs of all teeth except for the third molars were drawn and the lingual axis (LA) point was marked with a compass to the nearest 0.1 mm. The LA point in incisors, canines and premolars was the midpoint of the LACC. In molars, the LA point was the midpoint between the mesial and distal LA points. Each tooth block was put on the table of the Nikon V-10 profile projector. We measured the lingual crown angulation and inclination at $\times 10$ magnification. Descriptive statistics, including mean and standard deviation, were calculated.

The lingual crown angulation was formed by the intersection of a line perpendicular to the basal plane and the long LACC. Lingual crown inclinations in the incisors and canines were formed by the intersection of a line perpendicular to the basal plane and a line connecting the LA point and the innermost point of the lingual gingival margin. Lingual crown inclinations in premolars and molars were formed by the intersection of a line perpendicular to the basal plane and a line tangential to the midpoint of the long LACC. The lingual crown angulation and inclination were based on the tracings of the LA and lingual outline of the clinical crown using a Nikon V-10 profile projector.

The measurements of lingual crown angulation and lingual crown inclination were made twice by a single investigator using the discontinuous method. We used the normal distribution method to test the distribution of values of angulation and inclination and the paired *t* test to examine the consistency of the values of two measurements. If a significant difference was found between the two measurements ($p < 0.01$), it was measured again. The mean of the two measurements was taken as the final value.

RESULTS

Figure 2 shows the mean lingual crown angulations of optimal occlusion. Mesial tipping occurred in all teeth except the upper second molars, the lower central incisors, and the lower lateral incisors. The greatest mesial tipping was observed in the lower second molars. The greatest distal tipping was revealed in the lower lateral incisors. The mean lingual crown inclination data for optimal occlusion are shown in Figure 3. Labial/buccal inclination occurred in all teeth except the lower first molars and the lower

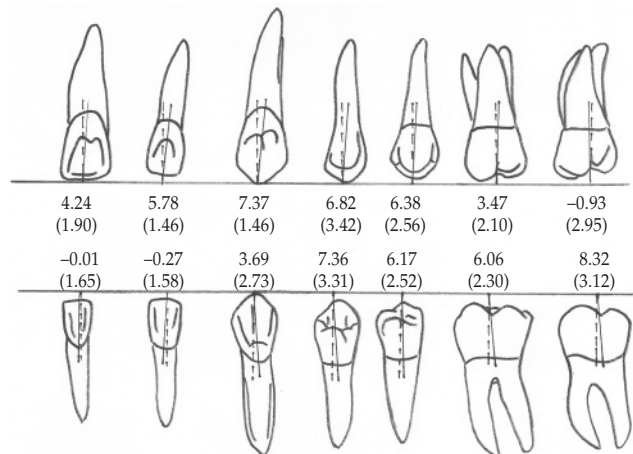


Figure 2. Lingual crown angulation of optimal occlusion; data shown as mean (standard deviation) in degrees.

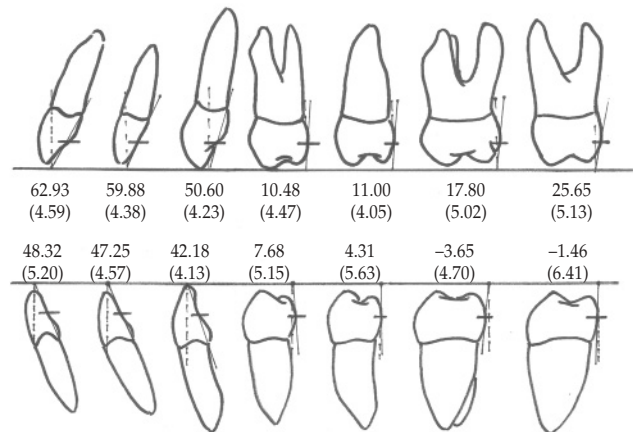


Figure 3. Lingual crown inclination of optimal occlusion; data shown as mean (standard deviation) in degrees.

second molars. Maximum labial inclination occurred in the upper central incisors. Maximum lingual inclination was observed in the lower first molars.

DISCUSSION

Sample selection

In this study, we selected a sample with optimal occlusion based on the “six keys to optimal occlusion” [9] and “ideal functional occlusion” [10,11]. Gorman et al [12] and Smith et al [13] pointed out that the lingual clinical crown height was often 30% less than that of the facial surface of the same tooth, especially in the maxillary incisors and mandibular premolars. Partially erupted, fractured, or worn teeth and

congenitally small teeth, such as peg laterals, present problems for samples. Therefore, we took dental casts using Gottlieb's grading system [14].

Basal plane

The occlusal plane was transferred to the basal plane of the casts. However, there are different definitions of the occlusal plane. Lundquist and Luther indicated that the occlusal plane was determined by a line from the mandibular cuspid tip to the distolingual cusp tip of the last mandibular molar [15]. Van der Linden and Boersma described the occlusal plane as an image plane constructed with the buccal cusp tips of the upper first premolars and the mesiobuccal cusp tips of the upper first molars [16]. Sebata [6], Choi [7], and Chen and Chang [8] defined the occlusal plane from the right or left upper central incisal edge and the distobuccal cusp tip of the right and left first molars. Ugur and Yukay constructed the occlusal plane with the buccal cusp tips of the lower premolars and first molars, which is comparable to the functional occlusal plane [2].

Orthodontic treatment is mostly executed before complete eruption of the second molar when the distobuccal cusp tips are slightly extruded more occlusally than the mesiobuccal cusp tips in the upper first molars. Therefore, we chose the distobuccal cusp tips of the right and left upper first molars and the incisal edge of the upper central incisor as reference points for the occlusal plane.

Lingual axis of clinical crown and lingual axis point

We used the LACC and LA point as reference marks. The long axis of the anatomic crown, long axis of the whole tooth, incisal edge, marginal ridge, and contact point are not reliable reference indices. Even though incisal edges or cusp tips are distinctive reference marks, they are prone to attrition and fracture. The marginal ridges of the clinical crown are far away from the bracket positions. Bracket positioning was difficult. The contact points of a tooth are difficult to identify, which decreases practicability.

Clinical lingual crown angulation

Due to the difference in the selection of the basal plane and the measurement method, we did not compare our results with those of other studies. In general, lingual crown angulations were positive, meaning that there was a tendency to mesial tipping in all teeth. The positive values for upper anterior teeth were greater than those of posterior teeth. These findings are similar to those in other studies [17,18]. Detailed data were given previously [19].

Clinical lingual crown inclination

In general, labial/buccal inclination occurred in all teeth except the lower first molars and the lower second molars. Maximum labial inclination occurred in the upper central incisors. Maximum lingual inclination occurred in the lower first molars. This means that there was a tendency to labial/buccal inclination of upper teeth and lingual inclination of lower molar teeth. These findings are similar to those of other investigations [17,18]. We did not compare our results with those of other studies due to the differences in basal plane and measurement methods. We have discussed these data previously [19].

In summary, we presented lingual crown angulations and inclinations of optimal occlusion in Taiwanese people. One of the criteria for obtaining a functional occlusion is to have an ideal dental arch form at the end of orthodontic treatment. A study of dental arch form of optimal occlusion in lingual orthodontics has been described elsewhere [19, 20].

ACKNOWLEDGMENTS

We thank Dr. Wen-Dyi Wang and Dr. Hui-Chun Chen for their help with data collection. This study was partially supported by the National Science Council of Taiwan (NSC 81-0412-B-037-34).

REFERENCES

1. Tweed CH. *Clinical Orthodontics*. Vol. 1. St. Louis: CV Mosby, 1966.
2. Ugur T, Yukay F. Normal faciolingual inclinations of tooth crowns compared with treatment groups of standard and pretorqued brackets. *Am J Orthod Dentofac Orthop* 1997;112: 50-7.
3. Andrews LF. *Straight Wire Concept and Appliance*. San Diego, California: LA Wells, 1989.
4. Fujita K. New orthodontic treatment with lingual bracket mushroom arch wire appliance. *Am J Orthod* 1979;76:657-75.
5. Alexander CM, Alexander RG, Gorman JC, et al. Lingual orthodontics: a status report. *J Clin Orthod* 1982;16:255-62.
6. Sebata E. An orthodontic study of the teeth and dental arch-form on the Japanese normal occlusion. *J Tokyo Dent Coll Soc* 1980;80:945-69.
7. Choi S. An orthodontic study of the teeth and dental arch-form of Koreans with normal occlusion. *J Tokyo Dent Coll Soc* 1984; 84:1055-76.
8. Chen HC, Chang HP. An orthodontic study of tooth morphology on the optimal occlusion in Taiwan. *J Taiwan Assoc Orthod* 2001;13:10-6.

9. Andrews LF. The six keys to normal occlusion. *Am J Orthod* 1972;62:296–309.
10. Roth RH. Functional occlusion for the orthodontist. *J Clin Orthod* 1981;15:32–51.
11. Roth RH. Orthodontic treatment goals and functional occlusion. *Am J Orthod* 1978;73:195.
12. Gorman JC, Hilgters JJ, Smith JR. Lingual orthodontics: a status report. Part 4: diagnosis and treatment planning. *J Clin Orthod* 1983;17:26–35.
13. Smith JR, Gorman JC, Kurz C, et al. Keys to success in lingual therapy. Part 1. *J Clin Orthod* 1986;20:252–61.
14. Gottlieb EL. Grading your orthodontic treatment results. *J Clin Orthod* 1975;9:155–61.
15. Lundquist DO, Luther WW. Occlusal plane determination. *J Prosthet Dent* 1970;23:489–98.
16. van der Linden FPGM, Boersma H. *Diagnosis and Treatment Planning in Dentofacial Orthopedics*. London: Quintessence, 1987.
17. Kurz C, Swartz ML, Andreiko C. Lingual orthodontics: a status report. Part 2: research and development. *J Clin Orthod* 1982;16:735–40.
18. Fujita K. Development of lingual bracket technique. Part 3. *J Jpn Orthod Soc* 1978;57:729–40.
19. Tseng YC, Chang HP. *A Study of Tooth Morphology and Dental Arch Form in Lingual Orthodontics*. Master thesis, Kaohsiung Medical University, Graduate Institute of Dental Sciences, 1998.
20. Tseng YC, Chang HP. A study of dental arch form in lingual orthodontics. *J Taiwan Assoc Orthod* 1998;10:3–14.

牙齒形態測量學的舌側矯正學研究

曾于娟¹ 張宏博² 周肇茂²

¹ 高雄醫學大學附設醫院 齒顎矯正科

² 高雄醫學大學 口腔醫學院

本研究的目的，在於建立國人正常咬合者牙冠舌側形態的資料，作為臨床舌側矯正的參考。從大約 5,000 名高中與大專院校學生，印取 45 組最接近理想咬合者的牙科模型 (男 28 人，女 17 人) 作為研究樣本。測量牙冠舌側近遠心傾斜與頰舌側傾斜角度，結果顯示，上顎除第二大臼齒以外，其他牙齒皆為近心傾斜，最大近心傾斜為犬齒。下顎除正門齒與側門齒以外，其他牙齒皆為近心傾斜，最大近心傾斜為第二大臼齒，最大遠心傾斜則為側門齒。上顎皆為唇 (頰) 側傾斜，最大唇 (頰) 側傾斜為正中門齒。下顎除第一、二大白齒以外，其他牙齒皆為唇 (頰) 側傾斜；最大唇 (頰) 側傾斜為正門齒，最大舌側傾斜則為第一大臼齒。

關鍵詞：舌側矯正，舌側牙冠斜角，舌側牙冠傾角
(高雄醫誌 2004;20:586-90)

收文日期：93 年 8 月 23 日

接受刊載：93 年 11 月 17 日

通訊作者：張宏博醫師

高雄醫學大學口腔醫學院

高雄市 807 十全一路 100 號