

# HINDFOOT ARTHRODESIS FOR NEUROPATHIC DEFORMITY

Peng-Ju Huang,<sup>1,2</sup> Yin-Chih Fu,<sup>3</sup> Cheng-Chang Lu,<sup>3</sup> Wen-Lan Wu,<sup>4</sup> and Yuh-Min Cheng<sup>2,3</sup>

<sup>1</sup>Department of Orthopedics, Kaohsiung Municipal Hsiao-Kang Hospital, <sup>2</sup>Department of Orthopedics, Faculty of Medicine, College of Medicine, Kaohsiung Medical University, <sup>3</sup>Department of Orthopedics, Kaohsiung Medical University Hospital, and <sup>4</sup>Department of Sports Medicine, College of Medicine, Kaohsiung Medical University, Kaohsiung, Taiwan.

Acquired neurologic disorders of the foot lead to arthrosis, deformities, instabilities, and functional disabilities. Hindfoot arthrodesis is the current option available for irreducible or nonbraceable deformities of neuropathic feet. However, the role of ankle arthrodesis in these patients has been questioned because of high nonunion and complication rates. From 1990 to 2001, 17 cases of acquired neuropathic foot deformities were treated by four tibiototalcalcaneal (TTC) arthrodeses and 13 ankle arthrodeses. TTC arthrodesis was performed on cases with combined ankle and subtalar arthritis or cases whose deformities or instabilities could not be corrected by ankle fusion alone. There was no nonunion of TTC arthrodesis and seven ununited ankle arthrodeses were salvaged by two TTC-attempted arthrodeses and five revision ankle-attempted arthrodeses. Eventually in these cases, there was one nonunion in TTC arthrodesis and one nonunion in revision ankle arthrodesis. The final fusion rate was 88% (15 of 17 cases) with average union time of 6.9 months (range, 2.5–18 months). The American Orthopaedic Foot and Ankle Society ankle hindfoot functional scores were evaluated: one was excellent (5.8%), seven were good (41%), eight were fair (53.3%), and one was poor (5.8%) in terms of total functional outcome. We conclude that TTC arthrodesis is indicated for cases with ankle and subtalar involvement and ankle arthrodesis is an alternative for cases with intact subtalar joint. We recommend revision ankle arthrodesis if the ankle fails to fuse and the bone stock of the talus is adequate. TTC arthrodesis is reserved for ankles with poor bone stock of the talus with fragmentation.

**Key Words:** ankle arthrodesis, neuropathy, tibiototalcalcaneal arthrodesis  
(*Kaohsiung J Med Sci* 2007;23:120–7)

Adult-acquired neurologic disorder of the foot leads to deformities and functional disabilities. They are often treated by either orthotic or soft-tissue procedures such as tendon release, lengthening, or transfer. However, it is challenging particularly if there are no suitable tendons available for transfer or if there are

co-existing irreducible deformities. At present, surgical options for such severe unstable or unbraceable deformities include triple, pantalar, tibio-calcaneal, or tibiototalcalcaneal (TTC) arthrodesis, which have been recommended in recent reports [1–3]. The aim of arthrodesis is to stabilize the foot in a functional position. Successful fusion has been difficult to achieve because of the relatively high complication rate [4,5], and ankle arthrodesis for such cases has rarely been recommended [4,6,7]. Since fusion of a hindfoot joint may alter the foot biomechanics, we believe that attempted fused joints should be kept to a minimum to avoid late sequelae. If successful ankle fusion can

Received: March 3, 2006      Accepted: September 25, 2006  
Address correspondence and reprint requests to: Dr Yuh-Min Cheng, Department of Orthopedic Surgery, Kaohsiung Medical University Hospital, 100 Shih-Chuan 1<sup>st</sup> Road, Kaohsiung 807, Taiwan.  
E-mail: K71058@knhk.kmu.edu.tw

be achieved, it may be a better option than TTC fusion, which sacrifices the subtalar joint.

## MATERIALS AND METHODS

From 1990 to 2001, 17 cases (eight males, nine females; mean age, 54.4 years) of acquired paralytic disabling ankles were treated by TTC or ankle arthrodesis and followed up for at least 1 year. The cases of paralytic foot included four peripheral nerve injuries (three common peroneal nerve and one sciatic nerve); four stroke with foot contractures; one traumatic brain injury with spastic foot; two iatrogenic sciatic palsy after spinal surgery; two poliomyelitis with ankle arthropathy; three diabetic neuroarthropathy with two of them having infection, and one case of suspected leprosy. There were 10 cases with arthritic change of ankle. The deformities included seven equinus, two varus, six equinovarus, one valgus and one calcaneovarus.

The goal of treatment for these acquired neuropathic deformed feet was the maintenance of functional position to keep patients brace-free with a stable and plantigrade painless ankle and hindfoot. Thirteen ankle arthrodeses and four TTC arthrodeses were performed on these patients. The indications for TTC fusion were: (1) combined ankle and subtalar arthritis; (2) severe deformity or instability that could not be corrected by ankle arthrodesis alone; and (3) inadequate bone stock of talus. Otherwise, ankle arthrodesis was indicated. The 13 ankle arthrodeses and four TTC arthrodeses were all performed with compression cross-screw fixation and the extensors were reefed to maintain the forefoot dorsiflexion through the same anterior incision. The ankle was fused in slight dorsiflexion rather than neutroflexion (because the compensatory Chopart joints motion is mainly plantarflexion rather than dorsiflexion after ankle arthrodesis) [8,9]. The other associated soft tissue procedures included four Achilles lengthening for equinus contracture and three split partial lateralization of anterior tibial tendon (SPLATT) to balance the varus deformities of the forefoot (Table). Short leg cast was applied postoperatively for 8–12 weeks until the regular follow-up X-ray showed callus formation, union of the arthrodesis, or nonunion.

There were seven nonunions in the attempted ankle arthrodeses (no union sign for at least 6 months after

primary fusion). These cases received salvage procedures by five revision ankle arthrodeses and two TTC fusion. In these revision cases, the postoperative casting period was prolonged until solid union. One case of malunion underwent salvage operation by revision ankle arthrodesis with corrective osteotomy for the over-corrected valgus deformity. Repeated debridement on a diabetic foot with infection (Table, case 15) resulted in huge bone defect and was filled with allograft when TTC fusion was performed after control of the infection. For the other cases, no bone graft was used.

At follow-up, weight-bearing X-rays were taken to check the union status and fusion alignment. The criterion of union was defined as the trabecular line passing through the attempted fusion site. The ideal fusion alignment is 0° to 5° hindfoot valgus; foot near neutroflexion to have a plantigrade foot when weight bearing. American Orthopaedic Foot and Ankle Society (AOFAS), ankle-hindfoot score comprising 40 points for pain, 50 points for function, and 10 points for alignment were evaluated at final follow-up and classified as the following: excellent (85–100 points), good (70–84 points), fair (45–69 points), and poor (0–44 points) [10].

## RESULTS

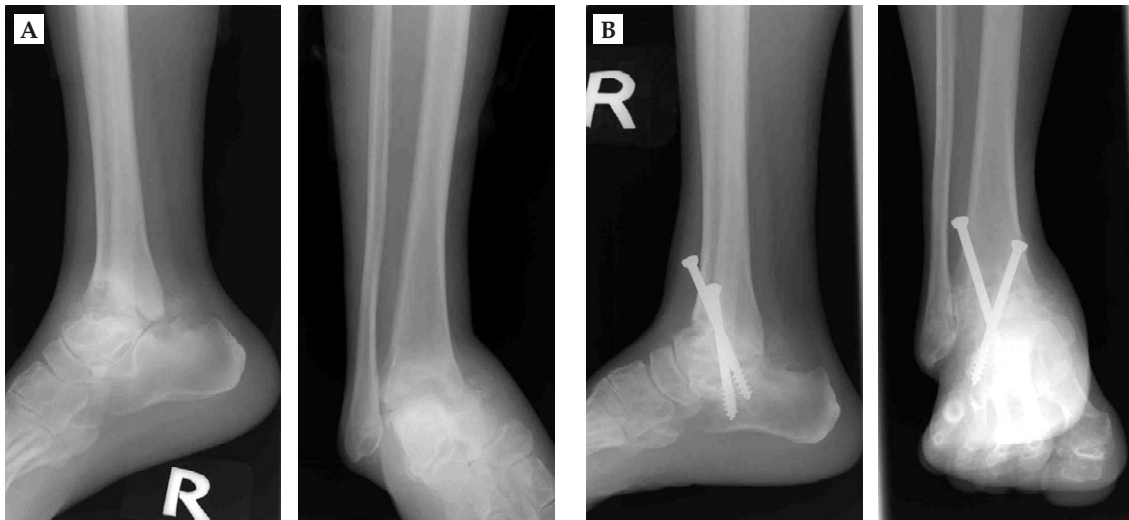These hindfoot arthrodeses for neurologic disorders of the foot were followed up for an average of 37 months (range, 12–108 months). The two cases of infection were controlled before arthrodesis was performed; there was no deep infection postoperatively but one case had partial skin necrosis with superficial infection. Of the four cases who received TTC arthrodesis, four ankle and three subtalar joints had union (Figure 1), but there were seven nonunions in 13 attempted ankle arthrodeses. There were five cases with under-correction and one case with over-correction of the deformities, which ended up as one plantarflex, one dorsiflex, one valgus, and three varus residual deformities. The mean union time for the primary arthrodesis cases was 6.6 months (range, 2.5–10.5 months).

The seven nonunion cases underwent salvage operation, which included five revision ankle arthrodesis (Figure 2) and two TTC arthrodeses. The fusion outcomes of revision arthrodeses were two nonunions

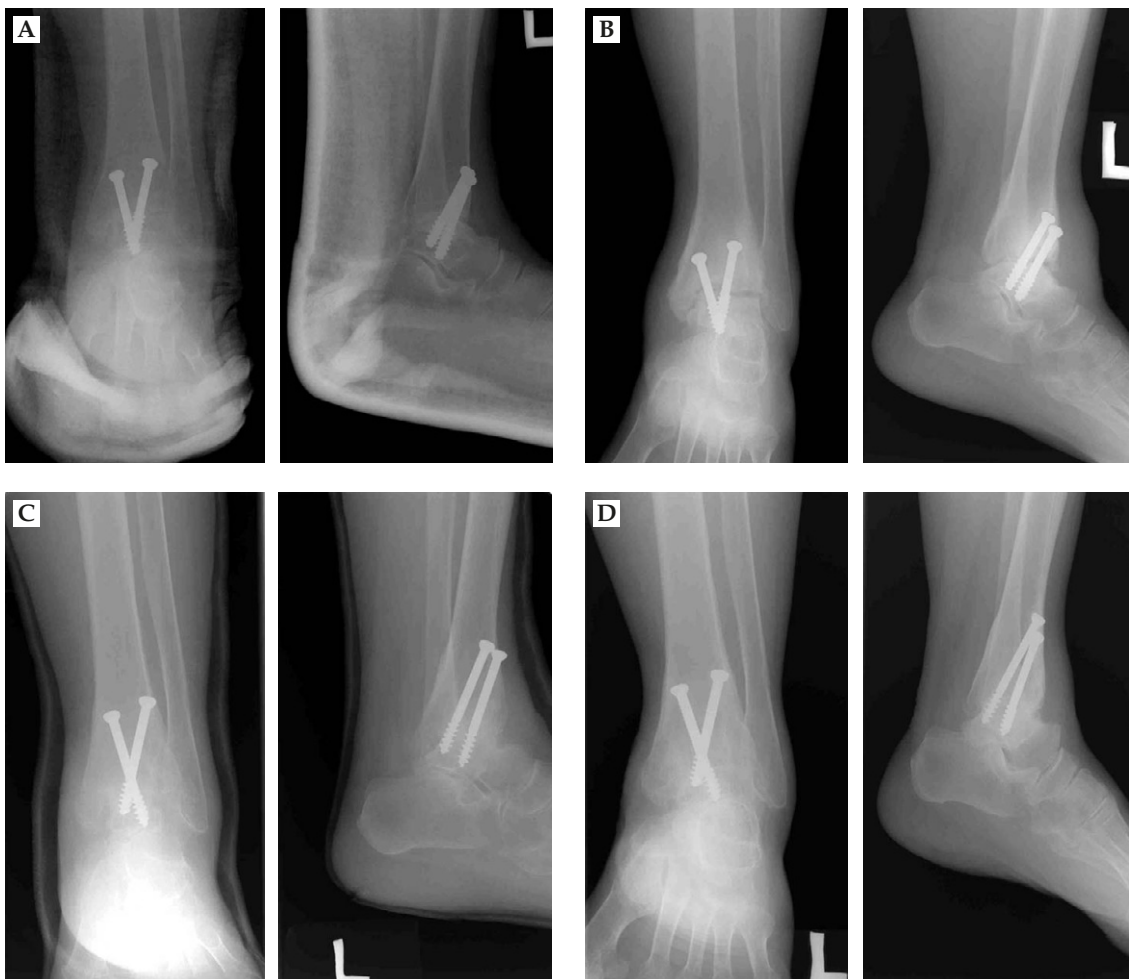
**Table. Management and outcome of neuropathic foot**

Case	Sex/ age (yr)	Etiology	Arthrosis	Deformity	Surgery	Outcome	Salvage op (op time)	Union time (mo)	Residual deformity	Follow- up (mo)	AOFAS score	Result
1	M/51	Traumatic peroneal palsy	+	Equinus contracture	TTC fusion and achilles lengthening	Union	-	10.5	Equinus	12	81 (40+36+5)	Good
2	M/70	DM arthropathy with infection	+	Varus	TTC fusion	Malunion (hyperdorsi)	-	10	Calcaneus	30	67 (40+22+5)	Fair
3	F/68	Iatrogenic sciatic palsy	-	Equinovarus	Ankle fusion	Nonunion	Revision ankle (12 mo)	4	-	30	52 (20+22+10)	Fair
4	F/50	R/O leprosy sciatic palsy	+	Calcaneovarus	Ankle fusion and SPLATT	Nonunion	TTC fusion (6 mo)	-	Forefoot varus	19	63 (30+28+5)	Fair
5	M/47	Traumatic peroneal palsy	-	Equinus contracture	Ankle fusion and achilles lengthening	Union	-	2.5	-	17	87 (40+37+10)	Excellent
6	M/40	Stroke sciatic palsy	-	Equinus spastic	Ankle fusion and SPLATT	Nonunion	Revision ankle (6 mo)	-	-	19	46 (20+16+10)	Poor
7	M/34	Poliomyelitis	+	Equinovarus	Ankle fusion	Malunion over correction	Revision ankle osteotomy (4 mo)	3	-	27	76 (40+26+10)	Good
8	F/54	Traumatic sciatic palsy	-	Equinus contracture	Ankle fusion and achilles lengthening	Union	-	2.5	-	48	83 (40+33+10)	Good
9	F/60	DM arthropathy	+	Varus	TTC fusion	Union	-	10	Varus	18	70 (30+35+5)	Good
10	F/65	Iatrogenic sciatic palsy	-	Equinus	Ankle fusion	Nonunion	Revision ankle (12 mo)	18	-	34	68 (30+28+10)	Fair
11	F/64	Stroke sciatic palsy	+	Equinovarus	Ankle fusion and CC fusion	Union	-	5.5	-	108	72 (40+22+10)	Good
12	F/73	Stroke peroneal palsy	+	Equinus	Ankle fusion	Union	-	4	-	78	82 (40+32+10)	Good
13	M/32	Head injury hemiplegia	-	Equinus contracture	TTC fusion	Union	-	4.5	-	96	66 (40+16+10)	Fair
14	F/32	Poliomyelitis arthropathy	+	Equinovarus	Ankle fusion	Union	-	6	Varus	50	52 (30+22+0)	Fair
15	F/65	DM arthropathy with infection	+	Valgus	Ankle fusion	Nonunion subtalar involved	TTC fusion (14 mo)	10	Hindfoot planus	24	64 (30+29+5)	Fair
16	M/63	Stroke sciatic palsy	-	Equinovarus spastic	Ankle fusion and SPLATT	Nonunion	Revision ankle (24 mo)	4	-	48	80 (40+30+10)	Good
17	M/35	Traumatic peroneal palsy	+	Equinovarus	Ankle fusion and achilles lengthening	Nonunion	Revision ankle (22 mo)	9	-	32	66 (30+26+10)	Fair

op = operation; AOFAS = American Orthopaedic Foot and Ankle Society; TTC = tibiotalar fusion; DM = diabetes mellitus; SPLATT = split partial lateralization of anterior tibial tendon; CC = calcaneocuboid fusion.



**Figure 1.** (A) This 60-year-old woman had diabetes mellitus with ankle joint varus deformity. (B) She received tibiotalar calcaneal fusion, and solid union was achieved.



**Figure 2.** (A) This 65-year-old woman had iatrogenic sciatic palsy with equinus deformity. She received ankle fusion. (B) There was still no sign of solid union 12 months later. (C) Revision ankle arthrodesis was performed and the period of cast immobilization was prolonged. (D) Ankle solid fusion was achieved after revision ankle arthrodesis.

with one in revision ankle and one in TTC arthrodesis at final follow-up, and the average union time was 9 months (range, 4–18 months).

The ultimate union rate of this series was 88% (15 of 17 cases). Of the six cases who finally still had ankle–hindfoot malalignment, only one case was severe enough to cause symptoms. The mean AOFAS ankle–hindfoot functional score was 68.4 (range, 46–87). Results included one excellent, seven good, eight fair, and one poor, according to the functional scores.

## DISCUSSION

Neuromuscular disorders that result in unstable arthropathy or unbraceable deformities are one of the relative indications for hindfoot arthrodesis. Long-term immobilization with either cast or brace is the mainstay treatment for neuropathic foot but it may not always be feasible [6,11,12], and conservative management is impossible especially in rigid deformities induced by soft tissue contracture. Reconstructive surgeries by arthrodesis, soft tissue procedures, or by both combined may be the preferred options. Foot deformities lead to abnormal foot pressure distribution which may result in callosity, pressure ulceration, and even infections that are difficult to treat. The neuropathic foot does not necessarily exhibit pain but the unbraceable deformities lead to ambulatory disability, and unsuitable bracing or casting may further create ulceration, especially in patients who lack protective sensation.

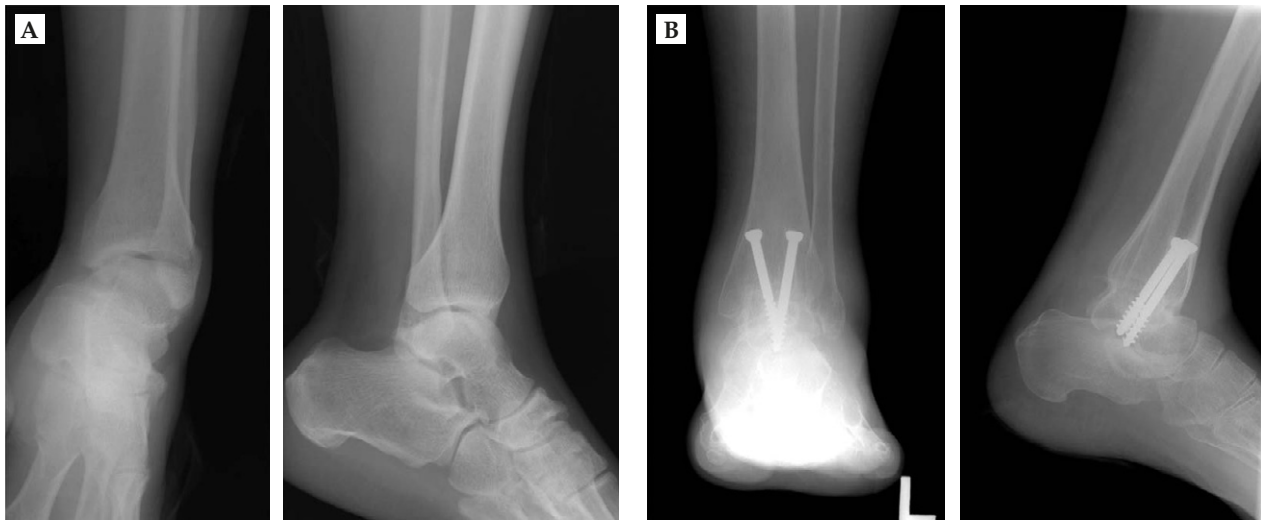
The goal of surgical treatment is to provide a stable, well-aligned foot which is brace-free and functioning. Successful fusion in the presence of neuroarthropathy has been difficult to achieve, and the rate of complications such as nonunion, malunion, and infection, etc. have been relatively high [4,5]. In our series, there were 10 cases with ankle arthrosis receiving arthrodesis. Of the remaining seven cases, five had contractures and two had floppy foot due to iatrogenic sciatic palsy after spinal surgery. Surgical treatment was indicated in all of these cases.

Hindfoot arthrodesis including ankle, subtalar, TTC, or tibiocalcaneal fusions is used to treat arthritis, to correct deformities and to provide stable painless weightbearing. Several reports of tibiocalcaneal arthrodesis exist in the literature. Three of these studies

mentioned neuroarthropathy with a union rate ranging from 36% to 93% [1,3,13]. Since the results are varied and have not been well documented, we consider that arthrodesis is indicated for cases in which the talar body has fragmentation and is eroded. As previous reports of ankle arthrodesis on neuropathic ankle had low success rates (Johnson [6], 33%; Samilson et al [7], 40%; Stuart and Morrey [5], 38%), TTC arthrodesis has been reported in the current decade [2,14]. This is indicated for severe deformity, instability, and arthritis that involve the ankle and/or subtalar joints. As for neuropathic cases, because of the well-documented difficulties in obtaining ankle fusion, they are also included as indications for TTC arthrodesis. However, concomitant fusion of the subtalar with the ankle does potentially alter the biomechanics of the foot and ankle [15]. It not only affects hindfoot but may alter forefoot motion as well. Since the remaining foot motion occurs in the Chopart and Lisfranc joints after hindfoot fusion, the subtalar must be fused in well-aligned eversion to allow normal Chopart joints motion, otherwise the Chopart joints will be locked and thus result in a rigid forefoot [16]. In our opinion, TTC fusion in neuropathic ankle should be indicated for combined subtalar arthritis or severe deformities and instabilities that cannot be corrected by ankle arthrodesis alone. If TTC fusion in neuropathic cases is only to provide a more rigid fixation to enhance ankle fusion, then the reason is not strong enough because in two studies, a nonunion rate of 14% [2] and 26% [17] were still reported. We reserve TTC arthrodesis as a salvage procedure in failed ankle fusion for the neuroarthropathic ankle.

In this series, the four cases of primary TTC arthrodesis achieved union in an average of 8.75 months; the remaining six of the 13 ankle-attempted arthrodeses had primary fusion in an average of 4.1 months (Figure 3). The union rate of ankle arthrodesis was comparable with previous reports [5–7], but with the same method of cross-screw compression, the fusion time was longer than that of our ankle arthrodesis performed for ankle arthrosis from other causes (average, 2.7 months [18]) and was closer to the union time of revision ankle arthrodesis (average, 4.6 months [19]). Our salvage operation for nonunion ankle arthrodesis included five revision ankle arthrodeses and two TTC arthrodeses. The revision arthrodesis was done by complete debridement to refresh the nonunion site till there was cancellous bony contact for fusion. Fixation





**Figure 3.** (A) This 47-year-old man had traumatic peroneal palsy with equinovarus deformity. (B) He received ankle arthrodesis and solid union was achieved 10 weeks after operation.

with compression cross screws was applied from tibia to talus in revision ankle arthrodesis and through the subtalar joint in TTC fusion with longer screws. No additional bone graft was used. Union of one TTC fusion and four ankle fusions were achieved in these secondary surgeries with the remaining two cases of nonunion (one TTC and one ankle) at final follow-up.

Excluding the two cases of nonunion (11.7%), the mean overall union time of primary and secondary fusion was 6.9 months. The four cases of primary TTC arthrodesis were successfully fused, but the union time (mean, 8.75 months) was longer than for successful primary ankle arthrodesis (mean, 4.1 months), and the TTC was not 100% successful in salvage operation, with one union and one nonunion. As for the primary ankle-attempted arthrodesis, although the union rate was lower than 50%, the union time was shorter than for TTC fusion. However, revision ankle arthrodesis achieved union in four of five cases which had failed to fuse by primary arthrodesis. With our limited experience of these few cases, we cannot deny the value of ankle arthrodesis and accept TTC arthrodesis as the standard procedure for neuropathic ankle arthrosis, deformities, and instabilities.

Ankle arthrodesis has been criticized in neuropathic cases mainly because of its high nonunion rate, and because it is difficult to achieve fusion between the long-axis tibia and the smaller surface of the talus. The following factors are especially important and must not be overlooked in neuropathic cases: complete denuding of joint cartilage and good cancellous bony

contact apposition, fixation with derotation and compression, and additional cast immobilization until solid fusion is achieved.

In our revision procedure for nonunion ankle arthrodesis, the remaining fibrocartilage was generally found in the attempted fusion site. If the fusion site has been well prepared to have a cancellous contact surface with good apposition and has been firmly fixed by internal compression method and prolonged casting for protection, then union can be achieved in revision cases [19] and neuropathic joints [20]. TTC arthrodesis is recommended for cases with subtalar involvement, and ankle arthrodesis is an option for cases with intact subtalar joint because it preserves some subtalar mobility and cushion effect, which is beneficial to hindfoot function. If the ankle arthrodesis fails to fuse, revision ankle arthrodesis can be considered as an alternative to TTC arthrodesis unless the talus is eroded and has fragmentation.

## REFERENCES

1. Alvarez RG, Barbour TM, Perkins TD. Tibiocalcaneal arthrodesis for nonbraceable neuropathic ankle deformity. *Foot Ankle Int* 1994;15:354-9.
2. Kile TA, Donnelly PA, Gehrke JC, et al. Tibiotalocalcaneal arthrodesis with an intramedullary device. *Foot Ankle Int* 1994;15:669-73.
3. Myerson MS, Alvarez RG, Lam PWC. Tibiocalcaneal arthrodesis for the management of severe ankle and hindfoot deformities. *Foot Ankle Int* 2000;21:643-50.

4. Shibata T, Tada K, Hashizume C. The result of arthrodesis of the ankle for leprotic neuroarthropathy. *J Bone Joint Surg* 1990;72A:749–56.
5. Stuart MJ, Morrey BF. Arthrodesis of the diabetic neuropathic ankle joint. *Clin Orthop* 1990;253:209–11.
6. Johnson JTH. Neuropathic fractures and joint injuries: pathogenesis and rationale of prevention and treatment. *J Bone Joint Surg* 1967;49A:1–30.
7. Samilson RL, Sankaran B, Bersani FA, Smith AD. Orthopaedic management of neuropathic joints. *AMA Arch Surg* 1959;78:115–21.
8. Cheng YM, Lin SY, Tien YC, Wu HS. Ankle arthrodesis. *Kaohsiung J Med Sci* 1993;9:524–31.
9. Wu WL, Su FC, Cheng YM, et al. Gait analysis after ankle arthrodesis. *Gait Posture* 2000;11:54–61.
10. Kitaoka HB, Alexander IJ, Adelaar RS, et al. Clinical rating systems for the ankle-hindfoot, midfoot, hallux and lesser toes. *Foot Ankle* 1994;15:349–53.
11. Laing PW, Coqley DI, Klenerman L. Neuropathic foot ulceration treated by total contact casts. *J Bone Joint Surg* 1992;74B:133–6.
12. Newman JH. Non-infective disease of the diabetic foot. *J Bone Joint Surg* 1981;63B:593–6.
13. Papa J, Myerson M, Girard P. Salvage with arthrodesis in intractable diabetic neuropathic arthropathy of the foot and ankle. *J Bone Joint Surg* 1993;75A:1056–66.
14. Russotti GM, Johnson KA, Cas JR. Tibiotalocalcaneal arthrodesis for arthritis and deformity of the hind part of the foot. *J Bone Joint Surg* 1988;70A:1304–7.
15. Gruen G, Mears D. Arthrodesis of the ankle and subtalar joint. *Clin Orthop* 1991;268:15–20.
16. Beaudoin A, Fiore S, Krause W, Adelaar R. Effect of isolated talocalcaneal fusion on contact in the ankle and talonavicular joints. *Foot Ankle Int* 1991;12:12–25.
17. Moore TJ, Prince R, Pochatko D, et al. Retrograde intramedullary nailing for ankle arthrodesis. *Foot Ankle Int* 1995;16:433–6.
18. Cheng YM, Huang PJ, Huang SH, et al. The surgical treatment for degenerative disease of the ankle. *Int Orthop* 2000;24:36–9.
19. Cheng YM, Chen SK, Chen JC, et al. Revision of ankle arthrodesis. *Foot Ankle Int* 2003;24:321–5.
20. Drennan DB, Fahey JJ, Maylahn DC. Important factors in achieving arthrodesis of the Charcot Knee. *J Bone Joint Surg* 1971;53A:1180–93.

# 神經病變併後足畸形的融合手術治療

黃鵬如<sup>1,2</sup> 傅尹志<sup>3</sup> 盧政昌<sup>3</sup> 吳汶蘭<sup>4</sup> 鄭裕民<sup>2,3</sup>

<sup>1</sup>高雄市立小港醫院 骨科

高雄醫學大學醫學院 <sup>2</sup>醫學系骨科學 <sup>4</sup>運動醫學系

<sup>3</sup>高雄醫學大學附設醫院 骨科

後天性足神經病變會造成關節炎、畸形、關節不穩定和功能受限。現今後足融合手術仍用來治療這些無法復位而且無法穿戴輔具的神經病變畸形足，雖然高未癒合率與高併發症有報告過。從 1990 年到 2001 年，共有 17 個後天神經病變畸形足接受治療，其中 4 個接受脛距跟骨融合，13 個接受踝融合。脛距跟骨融合用于踝關節與距下關節皆有關節炎侵犯。所有脛距跟骨融合病人都未發生未癒合情形，13 個踝融合病人則有 7 個發生未癒合，對於這 7 個病人，我們在 2 個病人用脛距跟骨融合治療，在 5 個病人用再一次踝關節融合治療。最後，2 個脛距跟骨融合有一個未癒合，而踝關節再融合也有一個未癒合。最終融合率是 88% (15/17)，平均所需癒合時間是 6—9 個月 (2.5 到 18 個月)，依照美國足踝關節學會踝後足評估表來看，有一個是優 (excellent)，有 7 個是好 (good)，有 8 個是一般 (fair)，有 1 個是不良 (poor)。後足畸形併神經病變的融合手術治療，若踝關節與距下關節都有侵犯，則適用脛距跟骨融合治療，若距下關節還完好，則適用踝關節融合治療，若踝關節融合失敗，脛距跟骨融合治療並非唯一選擇。可嘗試再一次踝關節融合，但若距骨磨損破裂變小，則脛距跟骨融合會是比较合適的選擇。

**關鍵詞：**踝融合，神經病變，脛距跟骨融合

(高雄醫誌 2007;23:120—7)

收文日期：95 年 3 月 3 日

接受刊載：95 年 9 月 25 日

通訊作者：鄭裕民教授

高雄醫學大學附設醫院骨科

高雄市807三民區十全一路100號