

LEIOMYOMA OF THE URINARY BLADDER: A CASE REPORT

Chung-Chin Chen, Chun-Hsiung Huang, Chang-Hung Chu, Chin-Ming Su,
Yii-Her Chou, Chee-Yin Chai,¹ and Ming-Chen Shih²

Departments of Urology, ¹Pathology, and ²Radiology, Kaohsiung Medical
University, Kaohsiung, Taiwan.

Leiomyoma of the urinary bladder is a rare tumor and constitutes 35% of benign mesenchymal bladder tumors. Herein, we report a case of leiomyoma of the bladder. A 32-year-old female was incidentally found to have an abnormal bladder mass on abdominal ultrasound during work-up for infertility. Bimanual examination then revealed a mass on the right side near the bladder neck area. On cystoscopic examination, an external compression mass covered with normal bladder mucosa could be seen at the right lateral wall. Computerized tomography revealed a homogeneous solitary tumor protruding into the urinary bladder from the right lateral wall without enlarged lymph nodes. Magnetic resonance imaging showed an intraluminal round mass at the right aspect of the urinary bladder, leading to suspicion of an intramural neurogenic or mesenchymal tumor. Surgical exploration was performed via a lower midline incision and a 5.0 × 4.5 × 2.2 cm mass was excised. The pathologic diagnosis was leiomyoma of the bladder. We discuss the diagnosis and management of leiomyoma of the bladder and briefly review the literature.

Key Words: leiomyoma, urinary bladder
(*Kaohsiung J Med Sci* 2003;19:141-5)

Leiomyomas are benign tumors that may be found at any site in the genitourinary tract. Benign mesenchymal tumors make up 1-5% of all bladder neoplasms, with leiomyoma representing the largest subgroup of these benign tumors [1]. Leiomyoma should be considered in the differential diagnosis of any bladder tumor. We report a case of leiomyoma of the bladder in a 32-year-old woman.

CASE PRESENTATION

This 32-year-old woman presented with infertility. She went to gynecologic clinics for help, complaining of recent urinary frequency and nocturia. Abdominal ultrasound revealed an abnormal bladder mass. She was transferred to our urology outpatient department for further management.

Pelvic examination revealed a mass on the right side near the bladder neck area. All parameters of routine blood samples, including hemogram and biochemistry, were within normal limits. Urinalysis demonstrated neither pyuria nor microscopic hematuria. On cystoscopic examination, an external compression mass covered with normal bladder mucosa could be seen at the right lateral wall.

Computerized tomography (CT) of the abdomen revealed a homogeneous solitary tumor protruding into the urinary bladder from the right lateral wall

Received: November 13, 2002 Accepted: January 21, 2003
Address correspondence and reprint requests to: Dr. Chun-Hsiung Huang, Department of Urology, Kaohsiung Medical University, 100 Shih-Chuan 1st Road, Kaohsiung City 807, Taiwan.
E-mail: chhuang@kmu.edu.tw

(Figure 1). No suspect or enlarged lymph nodes were demonstrated. Magnetic resonance imaging (MRI) of the pelvis showed an intraluminal round mass at the right aspect of the urinary bladder, and an intramural neurogenic or mesenchymal tumor was suspected (Figure 2). Surgical exploration was undertaken via a lower midline incision because malignancy could not be ruled out. During the operation, a retroperitoneal tumor arising from the bladder was removed. The size of the specimen was 5.0 x 4.5 x 2.2 cm. Grossly, it was white-gray in color and the surface was nodulated (Figure 3). Pathologic diagnosis was leiomyoma (Figure 4).

Convalescence was uneventful and the patient was discharged 1 week later. The patient remained well during 1 month of follow-up and no further urinary frequency and nocturia were noted.

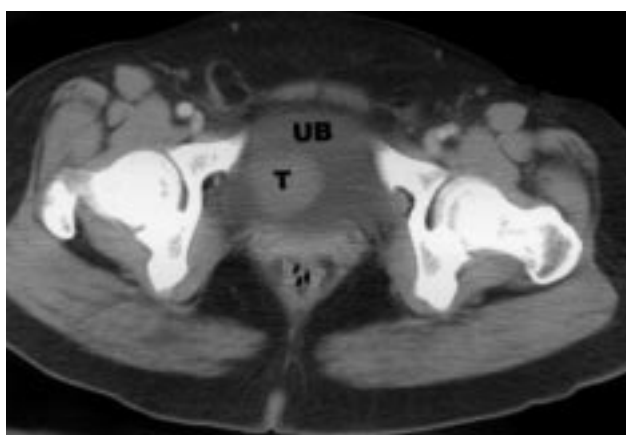

Figure 1. Axial contrast computerized tomography reveals a round homogeneous solitary tumor (T) protruding into the urinary bladder (UB) from the right lateral wall.

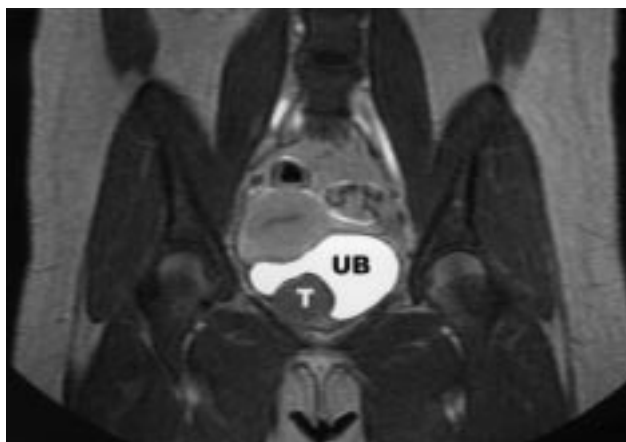


Figure 2. Magnetic resonance imaging demonstrates identical tumor (T) location in the urinary bladder (UB) with enhancement (T1-weighted, coronal view).

DISCUSSION

Leiomyoma of the urinary bladder is a rare tumor and constitutes 35% of benign mesenchymal bladder tumors [1]. These neoplasms occur in all age groups and appear to affect both sexes equally [2,3]. Most cases of urogenital leiomyoma have been described in Japanese publications [4]. This should be kept in mind as it may indicate a higher prevalence of this tumor in the Asian population [5].

Leiomyoma may develop in any layer and can be endovesical, intramural, or extravescical in location. The endovesical form has been reported in 63%, extravescical in 30%, and intramural in 7% of cases [6].

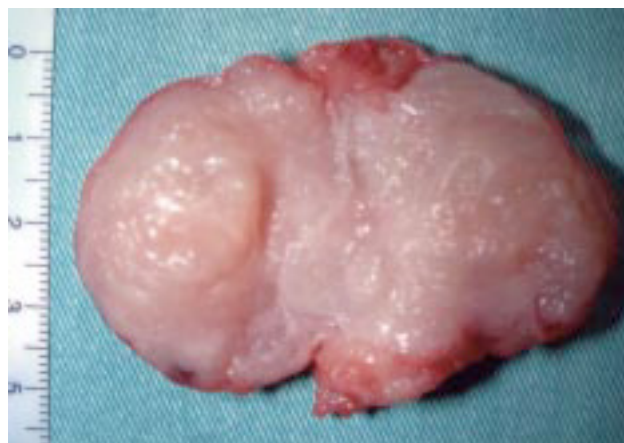

Figure 3. The specimen is 5.0 x 4.5 x 2.2 cm in size. Grossly, the mass is white-gray in color and the surface is nodulated.

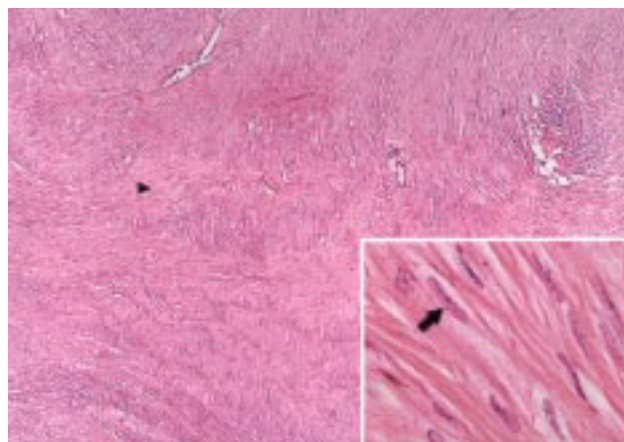


Figure 4. The tumor is formed of interlacing fascicles of spindle cells with usual cellularity and focal hyaline degeneration (arrowhead). (Hematoxylin & Eosin, original magnification x 40.) Tumor cells (arrow) have eosinophilic, fibrillar cytoplasm and uniform, vesicular, and bilateral blunt nuclei. (Hematoxylin & Eosin, original magnification x 400.)

Our patient had an intramural leiomyoma, which is the less usual form.

Goluboff et al reviewed all reported cases of leiomyoma of the bladder in the English literature since 1970 [7]. They indicated that obstructive voiding symptoms were the most common presenting patient complaint (49%). Of the remaining patients, 38% presented with irritative symptoms, 11% with hematuria, and 19% were asymptomatic. Knoll et al indicated that irritative voiding symptoms were the most frequent presenting symptom [6].

Besides a comprehensive history, a complete physical examination is important, because it has been reported that a palpable lesion is encountered in 57% of women who undergo bimanual examination [7]. Excretory urography or cystourethrography may identify a smooth filling defect in the bladder. Pelvic ultrasound may reveal a submucosal solid mass in the bladder. Real-time imaging can confirm the origin of the tumor in the bladder wall and its relationship to the uterus and vagina [8]. It has also been reported that transvaginal ultrasound may give accurate information about localization of the mass and its relation to adjacent organs [9].

CT has been used to detect leiomyoma of the bladder [10]. MRI of the bladder can differentiate mesenchymal tumors from the more common transitional cell tumors [11]. Leiomyoma of the bladder can be suspected from CT, ultrasound, and even excretory urography [6]. Unquestionably, however, MRI adds a new dimension to recognition and overall assessment of the tumor. Even MRI, however, cannot be relied on unfaithfully to differentiate leiomyoma from leiomyosarcoma, because both may be enhanced after contrast media administration. Thus, these apparently benign lesions should be removed completely and confirmed by pathologic examination [11].

Histologically, leiomyoma of the bladder may be clearly differentiated from leiomyosarcoma. Leiomyomas appear as whitish-gray round to ovoid nodules with spiral smooth muscle fibers. They are rubbery and firm in consistency. There are usually less than two mitotic figures per high-powered field [7]. Unlike this benign picture, leiomyosarcoma may have little mitotic activity microscopically but it usually has a large quantity of myxoid intracellular material and invades the muscularis propria. There are no reports of malignant degeneration of leiomyoma [12].

The treatment of leiomyomas is determined prima-

rily by their size and anatomic location [12]. In Goluboff et al's review, 62% were treated with open resection while 30% were treated with transurethral resection [7]. Small endovesical tumors can be resected transurethrally and only 18% have necessitated reoperation due to incomplete resection. Of the 62% who underwent open resection for large endovesical tumors, extravesical tumors, or intramural lesions, none required a second procedure. It has also been reported that leiomyoma of the bladder has been safely and effectively resected laparoscopically [13]. The low reoperation rate, absence of recurrence, and excellent prognosis of leiomyoma after surgical excision leaves the patient asymptomatic [12].

Pathologic and immunohistochemical findings of urinary leiomyomas are similar to uterine leiomyomas, which suggests hormonal influences as cofactors for the development of these tumors [14]. Uterine leiomyomas are an infrequent primary cause of infertility and have been reported as a sole cause in less than 3% of infertile patients [15]. This patient was infertile even though no uterine leiomyoma was noted on imaging studies. No association between urinary leiomyoma and infertility has ever been reported in the literature. Although the tumor was noted incidentally in this patient during work-up for infertility, there is no significant link between urinary leiomyoma and infertility.

In summary, we performed surgical excision in this patient because malignancy could not be ruled out after complete imaging studies. MRI provided three-dimensional images for preoperative planning and tumor localization. This helps the operator to identify and remove the tumor effectively. So, MRI may be helpful for suspected bladder mesenchymal tumor.

REFERENCES

1. Campbell EW, Gislason GJ. Benign mesothelial tumors of the urinary bladder: review of literature and a report of a case of leiomyoma. *J Urol* 1953;70:733-42.
2. O'Connell K, Edson M. Leiomyoma of bladder. *Urology* 1975; 6:114-7.
3. Katz RB, Walsbaum RS. Benign mesothelial tumor of bladder. *Urology* 1975;5:236.
4. Nishiyama H, Nakamura K, Nishimura M, et al. Male bladder leiomyoma: a case report. *Hinyokika Kyo* 1992;38:949-52. [In Japanese]
5. Broessner C, Klingler CH, Bayer G, et al. A 3,500-gram leiomyoma of the bladder: case report on a 3-year follow-up after surgical enucleation. *Urol Int* 1998;61:175-7.

6. Knoll LD, Segura JW, Scheithauer BW. Leiomyoma of the bladder. *J Urol* 1986;136:906–8.
7. Goluboff ET, O'Toole K, Sawczuk IS. Leiomyoma of bladder: report of case and review of literature. *Urology* 1994;43:238–41.
8. Illescas FF, Baker ME, Welnerth JL. Bladder leiomyoma: advantages of sonography over computed tomography. *Urol Radiol* 1986;8:216–8.
9. Fernandez AF, Dehesa TM. Leiomyoma of the urinary bladder floor: diagnosis by transvaginal ultrasound. *Urol Int* 1992; 48:99–101.
10. Brant WE, Williams JL. Computed tomography of bladder leiomyoma. *J Comput Assist Tomogr* 1984;8:562–3.
11. Sundaram CP, Rawal A, Saltzman B. Characteristics of bladder leiomyoma as noted on magnetic resonance imaging. *Urology* 1998;52:1142–3.
12. Soloway D, Simon MA, Milikowski C, Soloway MS. Epithelioid leiomyoma of the bladder: an unusual cause of voiding symptoms. *Urology* 1998;51:1037–9.
13. Lyons TL, Lee T, Winer WK. Laparoscopic removal of a bladder leiomyoma. *J Am Assoc Gynecol Laparosc* 1998;5:423–6.
14. Matsuo H, Kurachi O, Shimoura Y, et al. Molecular bases for the actions of ovarian sex steroids in the regulation of proliferation and apoptosis of human uterine leiomyoma. *Oncology* 1999;57:49–58.
15. Buttram VC, Reiter RC. Uterine leiomyomata: etiology, symptomatology, and management. *Fertil Steril* 1981;36:433–45.