

# DIABETIC MUSCLE INFARCTION IN ASSOCIATION WITH TERLIPRESSIN THERAPY: A CASE REPORT

Yu-Hung Chang,<sup>1,3</sup> Feng-Chieh Yen,<sup>3</sup> Ming-Chia Hsieh,<sup>2,3</sup> Kun-Der Lin,<sup>1,3</sup>  
Shyi-Jang Shin,<sup>2,3</sup> and Shih-Chieh Hsin<sup>3</sup>

<sup>1</sup>Graduate Institute of Medicine, <sup>2</sup>Graduate Institute of Medical Genetics, College of Medicine, Kaohsiung Medical University, and <sup>3</sup>Division of Endocrinology and Metabolism, Department of Internal Medicine, Kaohsiung Medical University Hospital, Kaohsiung, Taiwan.

Diabetic muscle infarction (DMI) is a rare complication that often exists in long-standing diabetic patients. Clinically, it presents with pain, swelling and sometimes a palpable mass, and is often misdiagnosed as soft tissue infection. The aetiology of DMI is uncertain. We present the case of a type 2 diabetic patient with liver cirrhosis who was diagnosed with muscle infarction after being treated with terlipressin for gastrointestinal bleeding. This 45-year-old male complained of increasing pain in his right posterior thigh after treatment with terlipressin for 2 days. He was initially diagnosed with soft tissue infection, but he responded poorly to antibiotic treatment. Magnetic resonance imaging suggested acute muscle infarction. We performed a muscle biopsy and the pathologist reported that the muscle was necrotic. After 5 days of bed rest, the patient was able to walk and was discharged uneventfully.

**Key Words:** diabetic muscle infarction, terlipressin  
(*Kaohsiung J Med Sci* 2009;25:25–8)

Diabetic muscle infarction (DMI) is an under-recognized diabetic complication characterized by muscle pain and swelling. It usually occurs in subjects with long-standing diabetes and known microvascular complications. There are no useful biochemical markers for this disease and it can easily be misdiagnosed as soft tissue infection. The exact pathogenesis of DMI is unclear. This case report presents a type 2 diabetic patient who was diagnosed with DMI after being treated with terlipressin for gastrointestinal bleeding.

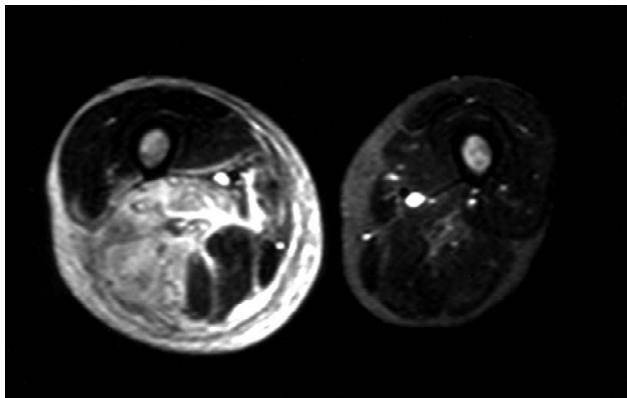
## CASE PRESENTATION

This 45-year-old male had been diagnosed with type 2 diabetes with nephropathy, retinopathy and neuropathy. He was also known to have hepatitis C-related liver cirrhosis and had experienced several episodes of esophageal varices and gastric ulcer bleeding prior to admission. On this occasion, he was brought to our hospital due to another episode of hematemesis. The patient refused gastroenteroscopy and his gastrointestinal bleeding was therefore treated with pantoprazole and terlipressin. After treatment for 2 days, he complained of increasing pain in his right posterior thigh. Physical examinations revealed a tender and swollen mass over his right posterior thigh. Laboratory data showed a white blood cell count of 8990/ $\mu$ L, C-reactive protein of 26.6 ng/mL, creatine phosphokinase of 359 U/L, and an erythrocyte sedimentation

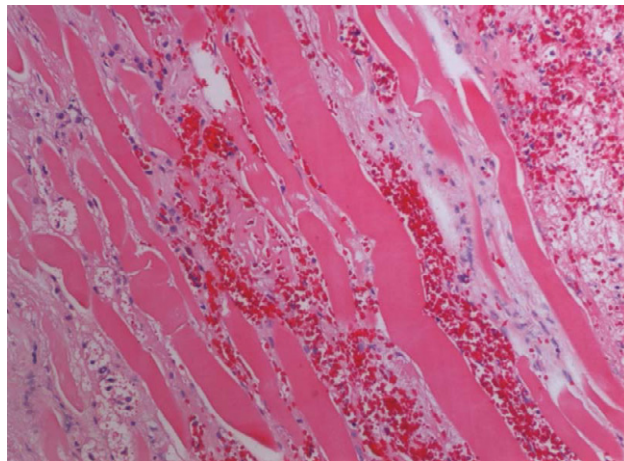


ELSEVIER

Received: Apr 20, 2008 Accepted: Jul 24, 2008  
Address correspondence and reprint requests to:  
Dr Shih-Chieh Hsin, Department of Endocrinology and Metabolism, Kaohsiung Medical University Hospital, 100 Shin-Chuan 1<sup>st</sup> Road, Kaohsiung 807, Taiwan.  
E-mail: bighorn1002@yahoo.com.tw



**Figure 1.** Axial T2-weighted, short tau inversion recovery, magnetic resonance imaging shows high signal intensity mainly in the hamstring muscle of the right thigh. Subfascial fluid accumulation is also seen.



**Figure 2.** Necrotic skeletal muscle cells without nuclei and surrounded by extravasated erythrocytes and inflammatory cells.

rate of 107 mm/hr. A soft tissue infection was initially suspected, for which he was treated with antibiotics. Because he responded poorly, we arranged for magnetic resonance imaging (MRI) (Figure 1). The radiologist strongly suspected that the patient could have acute muscle infarction, but that a muscle abscess could not be ruled out. To make an accurate diagnosis, we performed a muscle biopsy, and the pathologist reported that the muscle was necrotic (Figure 2). No microorganisms were detected. Based on these findings, the patient was diagnosed with DMI. Antibiotic treatment was discontinued and complete bed rest was advised. After 5 days hospitalization, the patient was able to walk and was discharged.

## DISCUSSION

Angervall and Stener reported the first case of DMI in 1965 [1]. Since then, slightly more than 100 cases have been reported in the English literature. DMI usually occurs in patients with long-standing diabetes, especially type 1 diabetes, with known late complications such as nephropathy, retinopathy, or neuropathy [2]. There is a slight female predominance and the mean age at presentation is about 43 years [2,3]. The most commonly involved sites are the quadriceps (62%), hip adductors (13%), hamstrings (8%), and hip flexor muscles (2%) [4].

Typical presentations of DMI include acute onset pain in the affected muscle, local swelling, and sometimes a palpable mass. Local heat and erythematous

appearance are not usually found on examination of the skin. The diagnosis must be differentiated from muscle strain, hematoma, myositis, fasciitis, abscess, deep vein thrombosis, and thrombophlebitis [5]. There are no useful biochemical markers for this disease, though increased plasma levels of creatine phosphokinase, a raised erythrocyte sedimentation rate, and raised leukocyte count might alert physicians of the possibility of DMI [2,3]. However, because these abnormalities are nonspecific and easily ignored, it is easy to initially misdiagnose DMI as soft tissue infection.

Nearly all patients with DMI have abnormal findings on MRI. Swollen and edematous muscles demonstrate increased signal intensity on T2-weighted, post-gadolinium sequences [6]. MRI also makes it possible to exclude other diseases that mimic DMI. Sonography is an alternative diagnostic tool; classic findings include a well-margined, hypoechoic, intramuscular lesion with features of internal linear echogenic structures coursing through the lesion [7]. DMI can be confirmed by muscle biopsy. Light microscopy will show irregular areas of hemorrhaging, muscle necrosis, and the appearance of granular tissue and collagen. Replacement of necrotic muscle fibers by fibrous tissue, myocyte regeneration, and mononuclear cell infiltration occurs in the late stages [8]. Although a definite diagnosis can be made by performing a muscle biopsy, this should be reserved for atypical cases [3,8].

The main treatment strategy includes bed rest and pain relief with analgesics. Surgical excision is not

recommended because it extends the length of hospital stay and has been associated with higher recurrence and mortality compared with nonsurgical treatment [9]. Symptoms usually resolve in approximately 4–8 weeks, though in nearly 50% of these patients, the disease may recur [4]. The long-term prognosis is generally poor, due to the coexistence of lethal macrovascular diseases. The mean mortality is 10% within 2 years from the onset of DMI [2].

The pathogenesis of DMI remains unclear. Some authors have suggested that it results from ischemia caused by embolization of atheromatous material [1,10]. However, arteriosclerosis obliterans has also been thought to be responsible [11]. Some authors have shown that alterations in the coagulation-fibrinolysis system and antiphospholipid syndrome might be involved [12,13]. In this case report, the patient developed DMI after being treated with terlipressin, a potent vasoconstrictor. Some reports in the literature have associated the use of terlipressin with serious cardiovascular events and ischemic colitis [14,15]. In this case, no abnormalities in the patient's coagulation system or phospholipid antibodies were detected during treatment, and magnetic resonance angiography of the affected leg revealed intact vascularity. Thus, it is probable that the vasoconstrictive effect of terlipressin worsened the blood flow in the affected muscles. Because the blood supply was impaired, the affected muscle swelled, leading to mild compartment syndrome, which further worsened the ischemia and resulted in muscle necrosis.

In summary, we report the first case of DMI probably caused by terlipressin. This report suggests that clinicians should be alert to the possibility of DMI when using vasoconstrictors in diabetic patients, especially those who are in the late stages of the disease and therefore often have compromised blood circulation.

## REFERENCES

1. Angervall L, Stener B. Tumoriform focal muscular degeneration in two diabetic patients. *Diabetologia* 1965;1:39–42.
2. Kapur S, Brunet JA, McKendry RJ. Diabetic muscle infarction: case report and review. *J Rheumatol* 2004;31:190–4.
3. Trujillo-Santos AJ. Diabetic muscle infarction: an underdiagnosed complication of long-standing diabetes. *Diabetes Care* 2003;26:211–5.
4. MacIsaac RJ, Jerums G, Scurrah L. Diabetic muscle infarction. *Med J Aust* 2002;177:323–4.
5. Rocca PV, Alloway JA, Nashel DJ. Diabetic muscular infarction. *Semin Arthritis Rheum* 1993;22:280–7.
6. Jelinek JS, Murphey MD, Abouafia AJ, et al. Muscle infarction in patients with diabetes mellitus: MR imaging findings. *Radiology* 1999;211:241–7.
7. Delaney-Sathy LO, Fessell DP, Jacobson JA, et al. Sonography of diabetic muscle infarction with MR imaging, CT, and pathologic correlation. *AJR Am J Roentgenol* 2000;174:165–9.
8. Grigoriadis E, Fam AG, Starok M, et al. Skeletal muscle infarction in diabetes mellitus. *J Rheumatol* 2000;27:1063–8.
9. Kapur S, McKendry RJ. Treatment and outcomes of diabetic muscle infarction. *J Clin Rheumatol* 2005;11:8–12.
10. Banker BQ, Chester CS. Infarction of thigh muscle in the diabetic patient. *Neurology* 1973;23:667–77.
11. Chester CS, Banker BQ. Focal infarction of muscle in diabetics. *Diabetes Care* 1986;9:623–30.
12. Galtier-Dereure F, Biron C, Vies M, et al. Vascular complications of diabetes mellitus: what role for phospholipid-binding antibodies? *Lupus* 1998;7:469–74.
13. Palmer GW, Greco TP. Diabetic thigh muscle infarction in association with antiphospholipid antibodies. *Semin Arthritis Rheum* 2001;30:272–80.
14. Schmitt W, Wagner-Thiessen E, Lux G. Ischaemic colitis in a patient treated with glypressin for bleeding oesophageal varices. *Hepatogastroenterology* 1987;34:134–6.
15. Rosario R, Lalanne B, Lebre P, et al. Myocardial infarction after injection of terlipressin for digestive hemorrhage. *Gastroenterol Clin Biol* 1996;20:712–3.

# Terlipressin 治療後發生糖尿病性肌梗塞 — 病例報告

張毓泓<sup>1,3</sup> 嚴逢杰<sup>3</sup> 謝明家<sup>2,3</sup> 林昆德<sup>1,3</sup> 辛錫璋<sup>2,3</sup> 辛世杰<sup>3</sup>

高雄醫學大學<sup>1</sup> 臨床醫學研究所<sup>2</sup> 醫學遺傳研所

<sup>3</sup>高雄醫學大學附設醫院 內分泌暨新陳代謝科

糖尿病性肌梗塞是一個非常少見的糖尿病併發症。通常發生在罹病期長的糖尿病患者。臨床表徵為一可以觸摸到疼痛、發漲的腫塊，而經常被誤判為軟組織感染。其致病因仍然不十分清楚。本病例報告一位罹患肝硬化的第 2 型糖尿病患者，因為上消化道出血而在接受 **terlipressin** 治療後發生了糖尿病性肌梗塞。他在接受 **terlipressin** 治療兩天後開始覺得右後大腿有越來越痛的情形。一開始診斷為軟組織感染並用抗生素治療，可是效果不佳。經過核磁共振 (**magnetic resonance imaging**) 檢查後判讀可能有急性肌肉梗塞。經由肌肉切片確診肌肉壞死。臥床休息 5 天之後，病人開始可以走動並平安出院。

**關鍵詞：**糖尿病性肌梗塞，**terlipressin**

(高雄醫誌 2009;25:25-8)

收文日期：97 年 4 月 20 日

接受刊載：97 年 7 月 24 日

通訊作者：辛世杰醫師

高雄醫學大學附設醫院內分泌暨新陳代謝科

高雄市三民區十全一路 100 號